

## Ultrasound-guided microwave ablation in the treatment of benign thyroid nodules in 435 patients

Yu-Jiang Liu, Lin-Xue Qian, Dong Liu and Jun-Feng Zhao

Department of Ultrasound, Beijing Friendship Hospital, Capital Medical University, Beijing 100050, China

Corresponding author: Lin-Xue Qian. Email: qianlinxue2002@163.com

### Impact statement

Ultrasound-guided MWA is an effective and safe technique for the treatment of benign thyroid nodules. It can significantly reduce the nodule volume, improve the patients' clinical symptoms, has less complication, guarantees quick recovery, meets patients' aesthetic needs, and shows less interference on the physiological and psychological aspects of the body. MWA should be a good complement to traditional open surgery and has potentials in clinical applications.

### Abstract

The objective of the present study was to investigate the effectiveness and safety of ultrasound-guided microwave ablation in the treatment of benign thyroid nodules. A total of 474 benign thyroid nodules in 435 patients who underwent ultrasound-guided microwave ablation from September 2012 to August 2015 were included. Nodule volume and thyroid function were measured before treatment and at 1, 3, 6, and 12 months and subsequently after every 6 months. The nodule volume reduction rate and changes of thyroid function were evaluated. The volume of all thyroid nodules significantly decreased after ultrasound-guided microwave ablation. The average volume was  $13.07 \pm 0.95$  ml before treatment, and  $1.14 \pm 0.26$  ml at 12-months follow-up. The mean volume reduction rate was 90% and the final volume reduction

rate was 94%. The volume reduction rate of mainly cystic nodules was significantly higher than that of simple solid and mainly solid nodules (all  $P < 0.05$ ). The pretreatment volume of nodules was positively correlated with the final volume reduction rate at final follow-up ( $P = 0.004$ ). No serious complications were observed after treatment. In conclusion, ultrasound-guided microwave ablation is an effective and safe technique for treatment of benign thyroid nodules, and has the potential for clinical applications.

**Keywords:** Microwave ablation, thyroid nodule, nodule volume, reduction rate, thyroid function, complications

*Experimental Biology and Medicine* 2017; 242: 1515–1523. DOI: 10.1177/1535370217727477

### Introduction

Thyroid nodule is a common clinical disease. Recently, paralleling with the development of imaging technology and treatment rate, the detection rate of thyroid nodules has been increasing yearly, even as high as 76% by high frequency ultrasound.<sup>1</sup> Most thyroid nodules are benign; some, however, display partially compressive symptoms or signs for malignant tendency and need to be treated.<sup>2,3</sup> To date, surgical resection is the main treatment for thyroid nodules. However, it has serious drawbacks such as leading to excessive surgical trauma or hypothyroidism, influencing the aesthetic aspect of the neck, or increasing a postoperative recurrence rate. The advantages of ultrasound-guided minimally invasive ablation therapy over the traditional surgery include simpler operation, shorter treatment time and lower treatment cost. Consequently, ultrasound-guided minimally invasive ablation therapy has drawn clinical attentions. Currently, the following types of minimally invasive ablation therapies are used to treat thyroid benign nodules: ethanol ablation (EA), laser ablation (LA), radiofrequency thermal ablation (RFA), and microwave ablation (MWA).<sup>4–7</sup>

MWA is a newly developed local thermal ablation technique that has fast heating speed, strong coagulation ability and large ablation zone, and has become a great therapeutic method in heat ablation therapy.<sup>8–10</sup> To the best of our knowledge, only two studies have been reported regarding thyroid nodules since the first publication by Feng *et al.*<sup>11</sup> However, the previous reports have potential limitations such as small sample size (ranging from 11 to 222),<sup>11,12</sup> and lack of measurement of thyroid function.<sup>11</sup>

The aim of this study was to evaluate the effectiveness and safety of ultrasound-guided MWA in the treatment of benign thyroid nodules using a larger sample size. In this study, we determined the nodule volume reduction rate (VRR) and changes of thyroid function during follow-up period.

### Materials and methods

#### Patients

A total of 474 benign thyroid nodules in 435 patients (126 males and 309 females; mean age:  $49.9 \pm 0.9$  years old; range: 24–76 years old) were treated with ultrasound-guided MWA from September 2012 to August 2015 in

Beijing Friendship Hospital. All nodules were examined through preoperative ultrasound-guided fine-needle aspiration cytology, and were confirmed to be benign pathologically. These benign nodules included: adenoma, multinodular goiter, old hematoma, glial retention cysts, and Hashimoto's thyroiditis that manifested as lumps in ultrasound findings. The 435 patients were selected based on the following inclusion criteria: (1) anxiety about thyroid nodules and willingness to undergo treatment; (2) presence of subjective symptoms such as neck discomfort or pain, difficulty in breathing or swallowing; (3) recurrence of thyroid nodules after total thyroidectomy; (4) overall poor condition that cannot tolerate surgery or unwillingness to undergo surgery due to aesthetic needs. The exclusion criteria included: (1) coagulation dysfunction, severe bleeding tendency, severe cardiopulmonary disease that cannot tolerate treatment; (2) puncture results that indicated follicular tumors or malignant tumors; (3) the ultrasound findings indicated as a highly malignant nodule (length diameter than transverse diameter, marked hypoechoic microcalcifications, ill-defined margins) although the biopsy results indicated benign; (4) presence of serious adhesion between nodules and trachea, esophageal, large blood vessels or recurrent laryngeal nerve that cannot be separated effectively.

The 474 thyroid nodules were classified into three categories based on the different components of the nodules: (1) 123 simple solid nodules (excluding cystic components); (2) 57 mainly solid nodules (solid portion >50%); (3) 294 mainly cystic nodules (cystic components >50%). An informed consent was obtained from each patient before treatment.

### Equipment

Sonograms for thyroid nodules were performed with Hitachi Ascendus color Doppler ultrasound diagnostic (L75-type high frequency linear array, frequency range: 5–18 MHz) before ablation and at each follow-up time. An MWA therapy instrument (KY-2000, Kangyou Medical, Nanjing, China) consists of a microwave generator, a flexible low-loss coaxial cable and a cooled shaft antenna. The generator is capable of producing 1–100 W of power at 2450 MHz. The antenna (a 100 mm shaft coated with polytetrafluoroethylene) is 16 G, needle type (3 mm in length), with stable temperature at 28–32°C. To prevent shaft from overheating, distilled water is circulated continuously through dual channels inside the antenna shaft, thus cooling the shaft.

### Pre-ablation preparation

Routine examinations of coagulation, thyroid function and related thyroid tissue autoantibodies (TT3, TT4, fT3, fT4, TSH, etc.) were performed before treatment. Patients with normal coagulation function were allowed to undergo the treatment. Patients with long-term use of anticoagulant drugs were required to stop at least three days before treatment. The location, size, blood flow of the nodules to be ablated, and the ablation range was determined through routine thyroid ultrasound and contrast-enhanced

ultrasound (CEUS) screening. The maximum diameter (d1) of the nodules and two vertical diameters (d2 and d3) were measured and then used to calculate the nodule volume using the following equation:  $\text{volume} = \pi/6 \times d1 \times d2 \times d3$ .

### Ablation procedure

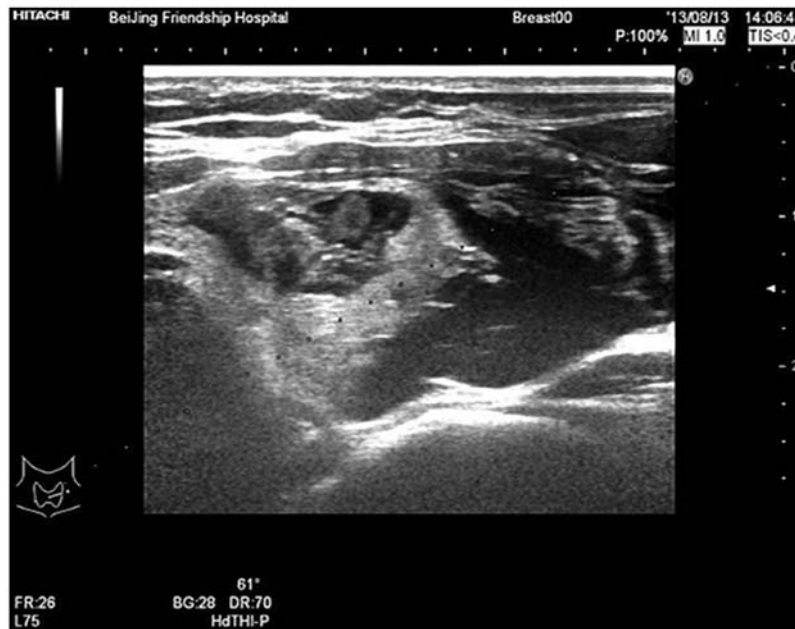The best puncture path and ablation were determined based on the size, location, blood flow, and internal components of thyroid nodules. During ablation, the patient was placed in the supine position with fully exposed neck, and then the operator prepared surgical area, locally anesthetized and open venous access for CEUS and intraoperative rescue. If the nodule to be ablated was adjacent to the ipsilateral recurrent laryngeal nerve or cervical large vessels, a mixture of 2% lidocaine (10 ml) and 0.9% physiological saline (20 ml) was infused into the surrounding thyroid capsule under ultrasound guidance to achieve a "liquid isolating region" (Figure 1) before ablation. The injection sites included: the area between thyroid anterior capsule and sternal hyoid muscle (to reduce pain stimulation to the muscle when performing the puncture needle and heat ablation), the area between thyroid lateral capsule and carotid artery (to increase the space between the arterial and glandular, and avoid destroying the arterial wall during the ablation process), and the area between the posterior thyroid capsule and the trachea or esophagus (to protect the recurrent laryngeal nerve from heat damage). For the mainly solid nodules, we performed MWA directly; for the mixed/mainly cystic nodules, however, we performed MWA only after aspiration of internal fluid.

Under ultrasound guidance, the pin of the microwave needle was pinned accurately into the nodules and microwave instrument started to perform MWA treatment, with a power output of 30–50 W. The ablation process was carried out under the ultrasonic dynamic monitoring. With the release of microwave energy, the echo from the microwave needle was enhanced and continued to expand. The "leverage pry-off method" was used during the ablation process to prevent recurrent laryngeal nerve, esophageal and other important structures from being destroyed by heat energy. A multi-point mobile ablation was needed for larger nodules. When the multi-angle scanning showed a strong change of echo after ablation and when Color Doppler flow imaging (CDFI) showed no blood flow signal in the nodules, CEUS was used to determine whether ablation was completed. The procedure stopped when the filling defect range of the nodules after ablation was greater than the enhanced range of the nodular before ablation.

All patients were kept under observation for more than 2 h after treatment, with local compression of the neck lasting 30 min. Finally, we reviewed the ultrasound examinations of the patients, recorded treatment time and any complications.

### Post treatment follow-up and examination

Thyroid ultrasonography was performed within one week, at one month, three months, and six months, and subsequently every six months after ablation. The size,



**Figure 1** The mixture of 2% lidocaine and 0.9% physiological saline was infused into the surrounding thyroid capsule under ultrasound guidance to achieve a “liquid isolating region” (arrows) before ablation

echogenicity, and intranodular vascularity of the nodules were examined, and the volume calculated. The VRR was calculated using the following equation:  $VRR (\%) = (\text{pretreatment volume} - \text{follow-up volume}) / \text{pretreatment volume} \times 100\%$ . Thyroid function (T3, T4, TSH) was also examined during the follow-up period.

### Statistical analysis

All statistical analyses were performed using SPSS 20.0 version. The volume and VRR of thyroid nodules before and after treatment were expressed by the mean  $\pm$  standard deviation (SD). The nodule volume after treatment at the follow-up period was compared with the pretreatment volume using the paired-samples *t*-test. The linear regression analysis was performed to examine the relationship between the pretreatment volume of the nodules and the final VRR. One-way ANOVA (analysis of variance) was used to assess the relationship between the compositions of the nodule and the VRR. A *P*-value less or equal 0.05 ( $P < 0.05$ ) was considered statistically significant.

## Results

### Ultrasonic image features

As shown in Figures 2 to 6, the volume of all thyroid nodules significantly decreased after ultrasound-guided MWA. Of 474 nodules, 368 were infused “liquid isolation region” (Figure 1) surrounding the thyroid capsule that was adjacent to the recurrent laryngeal nerve or neck blood vessels. During the ablation process, the nodules presented gasification strong echo, then 2 h after treatment, it changed to uneven low echoes with scattered hyperechoic spots in it. The lesions within the blood flow signal disappeared as observed through the CDFI, and no contrast agent filling in nodules, characterized by “black hole sign”

(Figures 2 and 3) as observed through CEUS, suggesting that the blood perfusion in nodular disappeared and ablation was completed.

### Follow-up results

The average volume of 474 nodules was  $13.07 \pm 0.95$  ml before treatment,  $3.49 \pm 0.23$  ml at 1 month,  $1.64 \pm 0.13$  ml at 3 months,  $1.60 \pm 0.20$  ml at 6 months, and  $1.14 \pm 0.26$  ml at 12 months, and  $0.38 \pm 0.07$  at the final follow-up period (Table 1). The nodular volume decreased progressively (Figures 4 to 8), and the differences were statistically significant ( $P < 0.05$ ) as compared with the volume before treatment. The VRR gradually increased by 9% at 1 month, 72% at 3 months, 81% at 6 months, 90% at 12 months, and 94% at the final follow-up period. The VRR of mainly cystic nodules was significantly higher than that of simple solid and mainly solid nodules (all  $P < 0.05$ ) (Figure 9). The pretreatment volume of nodules was positively correlated with the final VRR at the final follow-up ( $r = 0.599$ ,  $P < 0.01$ ).

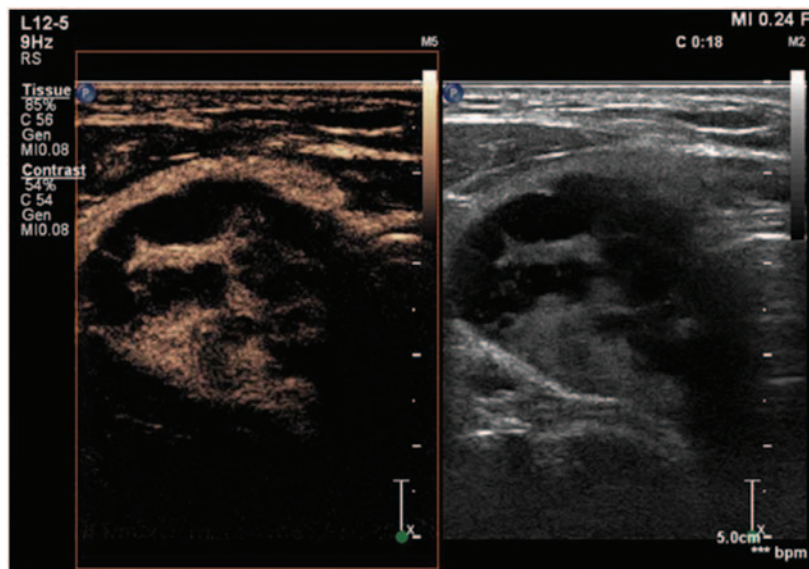
During the follow-up period, a total of 73 nodules completely disappeared, with the disappearance rate of 15.4%. After about six-months follow-up period, 46 nodules were ablated again due to lack of evident decrease in volume or recurrence of nodules. Eight of them had the third ablation at about one year after treatment. Finally, the VRR of the 46 nodules was greater than 50% and with no recurrence.

There were no significant differences in thyroid function (T3, T4, TSH) at 1, 3, 6, and 12 months after treatment compared with thyroid function before treatment ( $P > 0.05$ ) (Table 2).

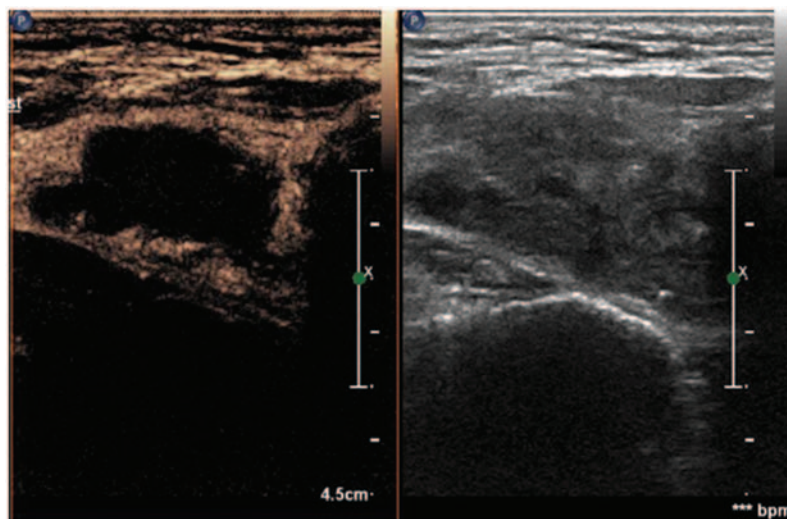
### Complications

**Thyroid hemorrhage.** Fifteen (3.2%) patients had intraoperative bleeding within the nodules, possibly due to





**Figure 2** CEUS showed that contrast agent was filling into the thyroid nodule before ablation process, indicating that the nodules had blood perfusion. (A color version of this figure is available in the online journal.)



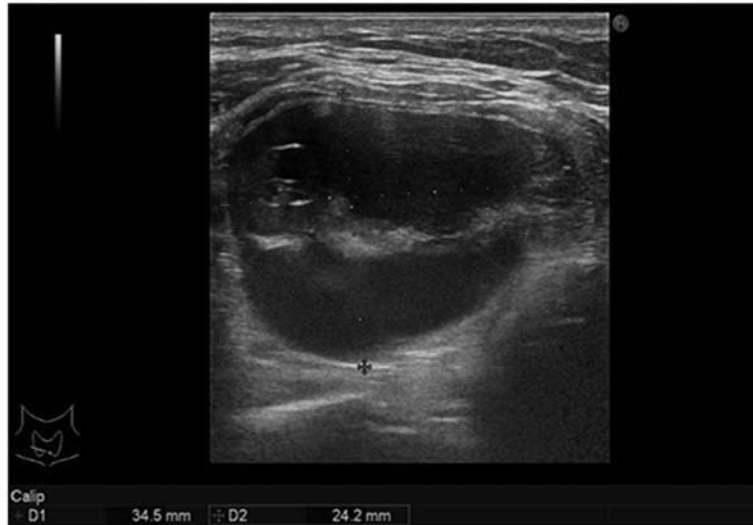
**Figure 3** CEUS showed that there was no contrast agent filling in nodule after aspiration of cyst fluid and ablation, indicating that the blood perfusion in nodule disappeared and ablation was completed. (A color version of this figure is available in the online journal.)

narrowing of cysts during aspiration of internal fluid, and injury of the solid composition during puncture using needle that leads to bleeding. The patients were treated with microwave needle with high-power at the bleeding points to stop bleeding, with timely local compression of 30–60 min, and were given hemostatic drug treatment if needed.

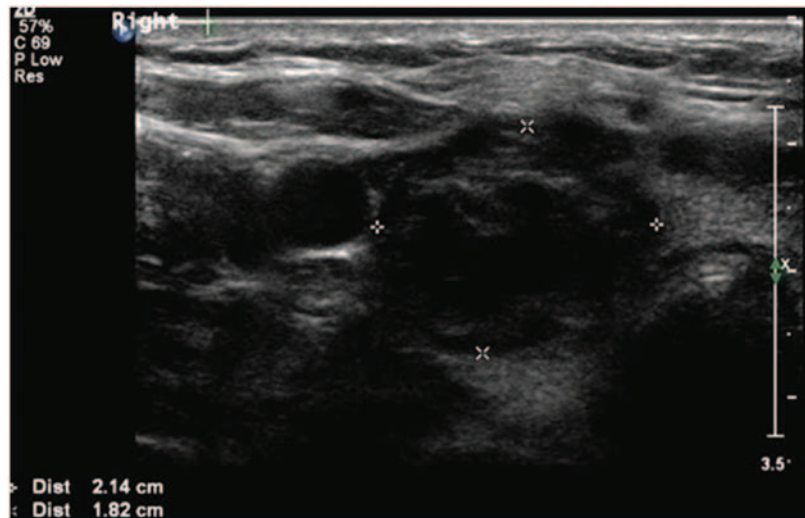
**Recurrent laryngeal nerve injury.** Three (0.6%) patients had hoarseness with a long duration (one to three months), possibly due to recurrent laryngeal nerve thermal injury during the process of MWA. The patients recovered after undergoing therapy with neurotrophic drug for three months and with none having permanent hoarseness.

**Neck burning sensation and pain.** Thirty-one (6.5%) patients had intraoperative or postoperative neck pain, with occasional radiation to the head, teeth, or shoulders. The complications were relieved when the treatment was suspended, or when the microwave power was reduced and, therefore, no analgesic drug was needed after treatment.

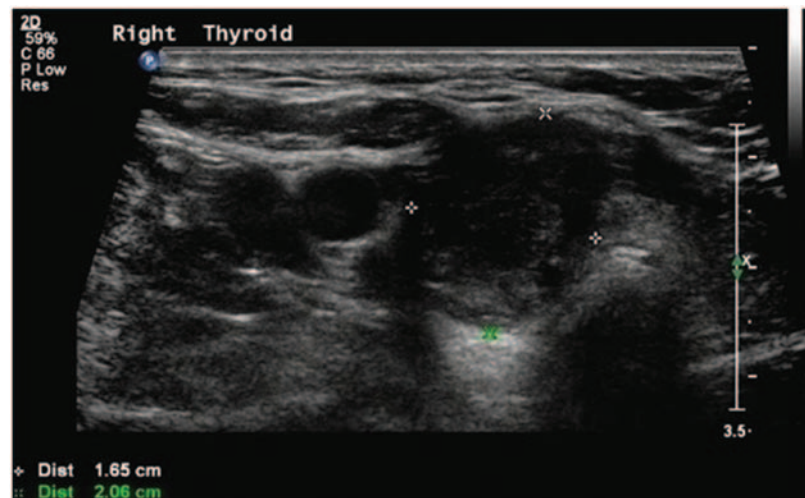
**Thyroid dysfunction.** Thyroid dysfunction occurred for six (1.3%) patients within one month after treatment. For four patients, only TSH decreased, whereas for the remaining two patients, TSH decreased together with an increase in either T3 or T4. No treatment was given because there



**Figure 4** A 64-year-old woman had a mainly cystic nodule in the right lobe of her thyroid gland (cystic components >50%). The pretreatment nodule size was  $3.7 \times 3.5 \times 2.4 \text{ cm}^3$ , and the volume was 16.25 ml



**Figure 5** At one month follow-up after ablation, the nodular size was  $2.6 \times 2.1 \times 1.8 \text{ cm}^3$ , the volume was reduced to 5.14 ml, and the VRR was 68.37%



**Figure 6** At three months follow-up after ablation, the nodular size was  $2.1 \times 2.1 \times 1.7 \text{ cm}^3$ , the volume was reduced to 3.92 ml, and the VRR was 75.88%

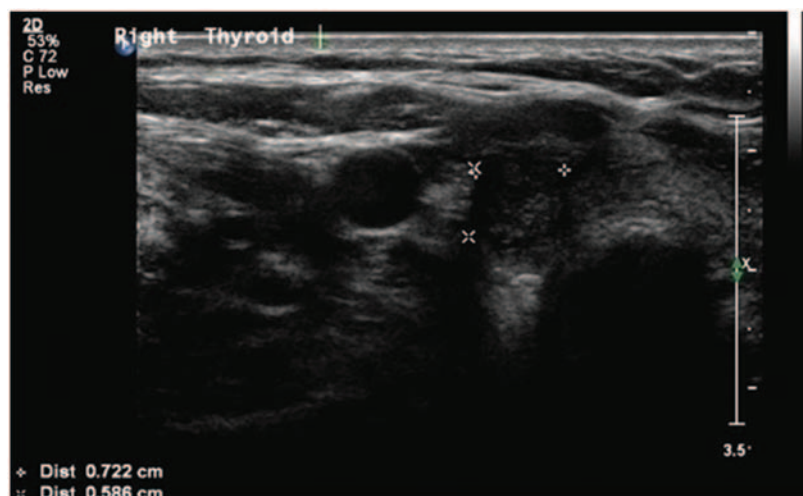
**Table 1** The changes in the nodule volumes before microwave ablation and at each follow-up period

	Baseline	1 month	3 months	6 months	12 months	Last follow-up
Whole group						
No. of nodules	474	351	252	228	210	474
Volume (ml)	13.07 ± 0.95	3.49 ± 0.23*	1.64 ± 0.13*	1.60 ± 0.20*	1.14 ± 0.26*	0.38 ± 0.07*
VRR		0.09 ± 0.23	0.72 ± 0.03	0.81 ± 0.03	0.90 ± 0.02	0.94 ± 0.01
Simple solid nodules						
No. of nodules	123	87	57	69	72	123
Volume (ml)	2.81 ± 1.25	1.87 ± 0.74*	1.52 ± 0.68*	1.03 ± 0.47*	0.83 ± 0.40*	0.50 ± 0.24*
VRR		-1.15 ± 0.69	0.53 ± 0.03	0.78 ± 0.06	0.86 ± 0.05	0.92 ± 0.03
Mainly solid nodules						
No. of nodules	57	39	39	24	30	57
Volume (ml)	3.02 ± 0.72	2.19 ± 0.61*	1.15 ± 0.28*	1.15 ± 0.28*	0.71 ± 0.20*	0.52 ± 0.22*
VRR		0.32 ± 0.04	0.62 ± 0.00	0.62 ± 0.00	0.78 ± 0.01	0.88 ± 0.04
Mainly cystic nodules						
No. of nodules	294	225	156	135	108	294
Volume (ml)	14.09 ± 3.26	4.37 ± 1.11*	2.84 ± 0.79*	1.87 ± 0.52*	1.15 ± 0.36*	0.53 ± 0.15*
VRR		0.62 ± 0.04	0.84 ± 0.02	0.90 ± 0.02	0.95 ± 0.01	0.97 ± 0.01

Note: Volume and VRR were expressed by the mean ± standard deviation (SD). Simple solid nodules (excluding cystic components); mainly solid nodules (solid portion >50%); mainly cystic nodules (cystic components >50%).

VRR: volume reduction rate.

\* $P < 0.01$ .



**Figure 7** At six months follow-up after ablation, the nodular size was  $1.1 \times 0.7 \times 0.6 \text{ cm}^3$ , the volume was reduced to 0.24 ml, and the VRR was 98.52%

were no obvious symptoms. The thyroid function for the six patients normalized three to six months after treatment.

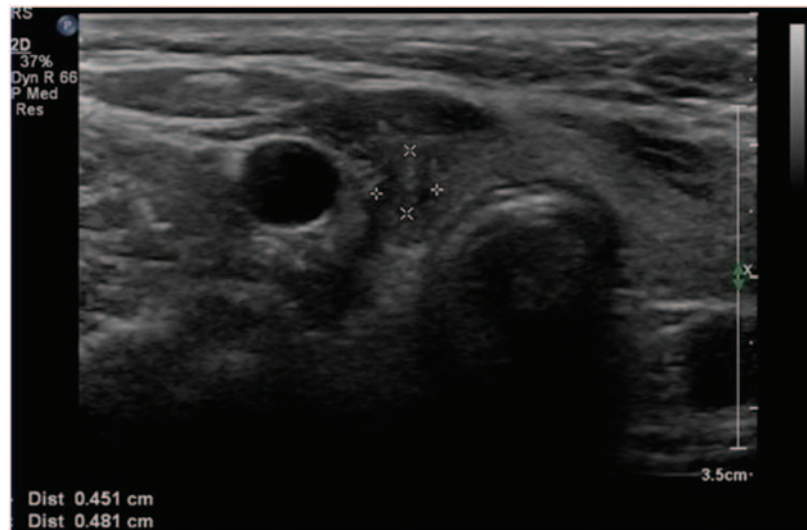
**Other complications.** No postoperative fever, infection, skin burns, neck damage or other important structural complications were observed.

## Discussion

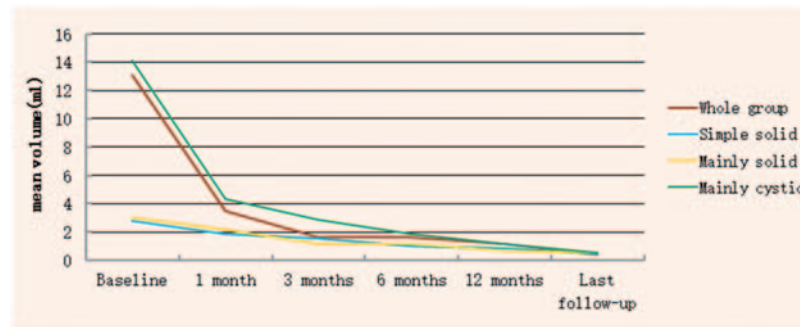
This study aimed to evaluate the effectiveness and safety of ultrasound-guided MWA in the treatment of benign thyroid nodules in a clinical setting. We found that the volume of all thyroid nodules significantly decreased after treatment. The VRR of mainly cystic nodules was significantly higher than

that of simple solid and mainly solid nodules. Furthermore, no serious complications were observed after treatment. The findings provide preliminary but important evidence for the potential clinical applications of ultrasound-guided MWA.

Thyroid nodule is the most common symptom and sign of thyroid diseases. With the increase of the detection rate and the incidence, choosing a more appropriate and effective treatment has become a hot topic in clinical research. Traditional surgical and radioactive $^{131}\text{I}$  treatments are the main treatment methods of thyroid nodules, but there are obvious disadvantages.<sup>13,14</sup> With the transformation of the medical model, patients not only require the cure of the lesions, but also to keep the neck as beautiful as possible,



**Figure 8** At 12 months follow-up after ablation, the nodular size was  $0.6 \times 0.5 \times 0.5 \text{ cm}^3$ , the volume was reduced to 0.08 ml, and the VRR was 99.51%



**Figure 9** The change trends of the average volumes of different types of thyroid nodules. (A color version of this figure is available in the online journal.)

**Table 2** The changes in thyroid function before and after microwave ablation

	T3	T4	TSH
Baseline	$3.15 \pm 0.37$	$0.92 \pm 0.17$	$2.86 \pm 3.76$
1 month	$3.17 \pm 0.27^*$	$0.95 \pm 0.14^*$	$3.12 \pm 1.47^*$
3 months	$3.05 \pm 0.23^*$	$0.89 \pm 0.37^*$	$2.76 \pm 2.37^*$
6 months	$3.22 \pm 0.28^*$	$0.97 \pm 0.23^*$	$1.92 \pm 1.41^*$
12 months	$2.98 \pm 0.57^*$	$0.93 \pm 0.16^*$	$2.65 \pm 2.37^*$

T3: triiodothyronine 3; T4: triiodothyronine 4; TSH: thyroid-stimulating hormone.  
\* $P < 0.05$ .

and therefore treatment of thyroid nodules is headed toward the development of minimally invasive methods.

EA is the earliest minimally invasive interventional therapy for benign thyroid nodules,<sup>15</sup> particularly for cystic thyroid nodules, and is recommended as a first-line treatment.<sup>16</sup> However, EA is not effective for solid or mainly solid thyroid nodules, mainly due to the uneven dispersion of ethanol in the solid nodules or the loss of ethanol caused

by the enrichment of nodular blood flow.<sup>16–18</sup> To address the drawbacks of EA, local thermal ablation technology such as LA, RFA, and MWA, was developed and gradually applied to treat benign thyroid nodules, leading to improved results.<sup>5,6,11,12,16–19</sup> Local thermal ablation is a hot topic in ultrasound-guided treatments for occupying lesions of various organs. The principle is to use thermal energy to make local tissue/cells undergo thermal degeneration and coagulation necrosis. One representative technique is RFA,<sup>20</sup> which can treat thyroid benign nodules effectively with fewer complications.<sup>19</sup> In contrast, the effect of LA in the treatment of benign thyroid nodules is relatively poor in terms of VRR<sup>12,21,22</sup> and safety compared with RFA.<sup>23</sup>

MWA is also a method of percutaneous thermal ablation. Compared with RFA and LA, MWA has the following advantages: producing higher energy, with a larger zone of ablation, shorter treatment time, more thorough tumor inactivation,<sup>11</sup> and particularly in the treatment of the thyroid nodules with larger volumes. Currently, there are very few reports on the treatment of benign thyroid nodules by MWA<sup>11,12</sup> and the follow-up period of these studies was relatively short (i.e. up to nine months). In this study, we



used the same treatment method for benign thyroid nodules with a longer follow-up (i.e. up to four years), and found that the average VRRs significantly decreased after treatment. And all patients did not have serious complications after treatment. Our findings are consistent with that in the report by Yue *et al.*,<sup>12</sup> suggesting that MWA have a good application prospect in the treatment of benign thyroid nodules. Furthermore, we found the VRR of mainly cystic nodules was significantly higher than that of simple solid and mainly solid nodules. This difference was more pronounced when considering the aspiration of internal fluid in cystic nodules and the easier absorption of the cystic components. The pretreatment volume of nodules was positively correlated with VRR at the final follow-up, which is consistent with previous reports.<sup>11,12</sup>

The aim of thyroid nodule heat ablation is to completely inactivate the nodules and achieve the purpose of cure. If nodules cannot be completely inactivated, residual tissue may lead to recurrence of nodules, and the recurrence rate ranges from 5.6% to 9.8%.<sup>19</sup> Although CDFI, CEUS and other methods were used to find residual tissues in time to add ablation during the ablation process, the scope of ablation is sometimes confined to the nodules to avoid injury to the adjacent structure and therefore postoperative residual is a common phenomenon, especially for larger nodules, which may require multiple ablations to achieve the goal of complete inactivation.<sup>24,25</sup> Jeong *et al.*<sup>24</sup> found nearly 1/3 nodules need two to six times to add ablation during follow-up period.<sup>24</sup> During follow-up period in this study, we found that 46 nodules needed secondary ablation, of which 8 nodules needed three times ablation, and ultimately achieved the purpose of complete inactivation. We suggested that three to six months after treatment is the best time to supplement the ablation, and the residual nodules are likely to have minimal size at that time, and therefore it is easy to sweep away the residuals at one time. If the waiting time is too long, the residual tissue recurred, nodular volume increased, and may increase the difficulty of ablation.

Because the thyroid gland is smaller and its adjacent structure is important and complex, complications are caused by improper operation or unfamiliar technical skill during the ablation process. Recurrent laryngeal nerve injury is a common and serious complication of thyroid nodule heat ablation.<sup>5,6,19,21,22,26</sup> The incidence of recurrent laryngeal nerve injury was rare in this study, and all were temporary recurrent laryngeal nerve injury. All patients recovered within three months after treatment. The post-operative analysis showed that the three patients had a larger nodule volume (> 50 ml) before treatment, the ablation time was relatively long, the fluid was not added in time to achieve "liquid isolation region," and the range of the ablation was too large that led to the thermal damage of the recurrent laryngeal nerve. Previous studies<sup>12,25</sup> demonstrated that the use of artificial "liquid isolation region" to assist ablation therapy is an effective and safety method when thyroid nodules were close to esophagus, trachea, and recurrent laryngeal nerves. It can deter thermal effects from stimulating the trachea and esophagus during ablation and prevent cough or pain that makes it

difficult for patients to tolerate the treatment process. Meanwhile, it can also protect the recurrent laryngeal nerve and improve the complete ablation rate of nodules at risk. If the operation is not correctly performed or nerve walking varied, the "liquid isolation region" method may also be invalid.

About 368 of 474 nodules were infused with "liquid isolation region" during the ablation process, which protected the recurrent laryngeal nerve. No patient had permanent hoarseness. In addition to the "liquid isolation region" technique, this study also used multi-point, multi-slice, mobile ablation technique<sup>22</sup> and "leveraged pry-off method" during the ablation process. These methods were effective to ensure complete ablation of thyroid nodules and the protection of peripheral vascular nerves. The procedure is particularly important for larger nodules or nodules adjacent to peripheral vascular nerves.

In summary, ultrasound-guided MWA is an effective and safe technique for the treatment of benign thyroid nodules. It can significantly reduce the nodule volume, improve the patients' clinical symptoms, has less complication, guarantees quick recovery, meets patients' aesthetic needs, and shows less interference on the physiological and psychological aspects of the body. MWA should be a good complement to traditional open surgery and has potentials in clinical applications.

**Authors' contributions:** Yu-Jiang Liu and Lin-Xue Qian equally contributed to the conception and design of the research; Dong Liu contributed to the acquisition and analysis of the data; Jun-Feng Zhao contributed to the interpretation of the data; and Yu-Jiang Liu drafted the manuscript. All authors critically revised the manuscript, agree to be fully accountable for ensuring the integrity and accuracy of the work, and read and approved the final manuscript.

#### DECLARATION OF CONFLICTING INTERESTS

The author(s) declared no potential conflicts of interest with respect to the research, authorship, and/or publication of this article.

#### REFERENCES

- Gharib H, Papini E, Paschke R, Duick DS, Valcavi R, Hegedus L, Vitti P. Nodules AAETFoT. American Association of Clinical Endocrinologists, Associazione Medici Endocrinologi, and European Thyroid Association Medical guidelines for clinical practice for the diagnosis and management of thyroid nodules: executive summary of recommendations. *Endocr Pract* 2010;**16**:468–75
- Weiss RE, Lado-Abel J. Thyroid nodules: diagnosis and therapy. *Curr Opin Oncol* 2002;**14**:46–52
- Klubo-Gwiedzinska J, Wartofsky L. Thyroid emergencies. *Med Clin North Am* 2012;**96**:385–403
- Kim JH, Lee HK, Lee JH, Ahn IM, Choi CG. Efficacy of sonographically guided percutaneous ethanol injection for treatment of thyroid cysts versus solid thyroid nodules. *Am J Roentgenol* 2003;**180**:1723–6
- Lee JH, Kim YS, Lee D, Choi H, Yoo H, Baek JH. Radiofrequency ablation (RFA) of benign thyroid nodules in patients with incompletely resolved clinical problems after ethanol ablation (EA). *World J Surg* 2010;**34**:1488–93



6. Jang SW, Baek JH, Kim JK, Sung JY, Choi H, Lim HK, Park JW, Lee HY, Park S, Lee JH. How to manage the patients with unsatisfactory results after ethanol ablation for thyroid nodules: role of radiofrequency ablation. *Eur J Radiol* 2012;**81**:905–10
7. Popoveniuc G, Jonklaas J. Thyroid nodules. *Med Clin North Am* 2012;**96**:329–49
8. Liang P, Dong B, Yu X, Yu D, Cheng Z, Su L, Peng J, Nan Q, Wang H. Computer-aided dynamic simulation of microwave-induced thermal distribution in coagulation of liver cancer. *IEEE Trans Biomed Eng* 2001;**48**:821–9
9. Wright AS, Lee FT Jr, Mahvi DM. Hepatic microwave ablation with multiple antennae results in synergistically larger zones of coagulation necrosis. *Ann Surg Oncol* 2003;**10**:275–83
10. Wright AS, Sampson LA, Warner TF, Mahvi DM, Lee FT Jr. Radiofrequency versus microwave ablation in a hepatic porcine model. *Radiology* 2005;**236**:132–9
11. Feng B, Liang P, Cheng Z, Yu X, Yu J, Han Z, Liu F. Ultrasound-guided percutaneous microwave ablation of benign thyroid nodules: experimental and clinical studies. *Eur J Endocrinol* 2012;**166**:1031–7
12. Yue W, Wang S, Wang B, Xu Q, Yu S, Yonglin Z, Wang X. Ultrasound guided percutaneous microwave ablation of benign thyroid nodules: safety and imaging follow-up in 222 patients. *Eur J Radiol* 2013;**82**:e11–6
13. Hegedus L, Bonnema SJ, Bencedbaek FN. Management of simple nodular goiter: current status and future perspectives. *Endocr Rev* 2003;**24**:102–32
14. Hegedus L. Clinical practice. The thyroid nodule. *N Engl J Med* 2004;**351**:1764–71
15. Livraghi T, Paracchi A, Ferrari C, Bergonzi M, Garavaglia G, Raineri P, Vettori C. Treatment of autonomous thyroid nodules with percutaneous ethanol injection: preliminary results. Work in progress. *Radiology* 1990;**175**:827–9
16. Ha EJ, Baek JH. Advances in nonsurgical treatment of benign thyroid nodules. *Future Oncol* 2014;**10**:1399–405
17. Kim YJ, Baek JH, Ha EJ, Lim HK, Lee JH, Sung JY, Kim JK, Kim TY, Kim WB, Shong YK. Cystic versus predominantly cystic thyroid nodules: efficacy of ethanol ablation and analysis of related factors. *Eur Radiol* 2012;**22**:1573–8
18. Spiezia S, Vitale G, Di Somma C, Pio Assanti A, Ciccirelli A, Lombardi G, Colao A. Ultrasound-guided laser thermal ablation in the treatment of autonomous hyperfunctioning thyroid nodules and compressive nontoxic nodular goiter. *Thyroid* 2003;**13**:941–7
19. Lim HK, Lee JH, Ha EJ, Sung JY, Kim JK, Baek JH. Radiofrequency ablation of benign non-functioning thyroid nodules: 4-year follow-up results for 111 patients. *Eur Radiol* 2013;**23**:1044–9
20. Kim YS, Rhim H, Tae K, Park DW, Kim ST. Radiofrequency ablation of benign cold thyroid nodules: initial clinical experience. *Thyroid* 2006;**16**:361–7
21. Dossing H, Bencedbaek FN, Hegedus L. Long-term outcome following interstitial laser photocoagulation of benign cold thyroid nodules. *Eur J Endocrinol* 2011;**165**:123–8
22. Baek JH, Lee JH, Valcavi R, Pacella CM, Rhim H, Na DG. Thermal ablation for benign thyroid nodules: radiofrequency and laser. *Korean J Radiol* 2011;**12**:525–40
23. Yang YL, Chen CZ, Zhang XH. Microwave ablation of benign thyroid nodules. *Future Oncol* 2014;**10**:1007–14
24. Jeong WK, Baek JH, Rhim H, Kim YS, Kwak MS, Jeong HJ, Lee D. Radiofrequency ablation of benign thyroid nodules: safety and imaging follow-up in 236 patients. *Eur Radiol* 2008;**18**:1244–50
25. Huh JY, Baek JH, Choi H, Kim JK, Lee JH. Symptomatic benign thyroid nodules: efficacy of additional radiofrequency ablation treatment session – prospective randomized study. *Radiology* 2012;**263**:909–16
26. Valcavi R, Riganti F, Bertani A, Formisano D, Pacella CM. Percutaneous laser ablation of cold benign thyroid nodules: a 3-year follow-up study in 122 patients. *Thyroid* 2010;**20**:1253–61

(Received May 8, 2017, Accepted July 25, 2017)