

sera are affected, and possibly split into smaller molecules. Since cancer processes alter serum globulins, this may be also the case with the alpha-2 macroglobulins.

The findings above suggest that the changes produced in alpha-2 macroglobulins by cancer processes should be further evaluated in relation to the development of a serological diagnostic test.

-
1. Oliver-González, J., Rivera de Sala, A., Cancio, M., Proc. Soc. Exp. Biol. and Med., 1964, v116, 409.
 2. Rivera, J. V., Toro Goyco, E., Am. J. Med. Sci., 1965, v249, No. 4.
 3. Manuscript in preparation.
 4. Yakulis, U. J., Heller, P., Amer. J. Clin. Path., 1959, v31, 323.
-

Received August 24, 1966. P.S.E.B.M., 1966, v123.

Effects of Early Embryectomy and Hormonal Therapy on the Fate Of the Placenta in Pregnant Rhesus Monkeys. (31609)

JOHN LEWIS, JR. AND ROY HERTZ*

Endocrinology Branch and Surgery Branch, National Cancer Institute, Bethesda, Md.

Early death of the embryo has been suggested as one of the possible etiological factors of hydatidiform mole, a complication of human pregnancy(1,2). That hypothesis was the basis for this study of the effects of embryectomy on the retained placenta in the rhesus monkey (*Macaca mulatta*). This species was selected because of the similarity of its placenta to the human placenta and because the diagnosis of pregnancy can be established early by testing for chorionic gonadotropin activity in the serum or urine from the 14th to the 35th day of gestation(3, 4,5).

It has been demonstrated in rabbits(6,7), rats(8), and monkeys(9) that careful removal of the embryo results in persistent viability and function of the placenta for the normal duration of gestation in a large percentage of the animals so treated. Van Wagenen and Newton(9) have shown that removal of the embryo from the rhesus monkey at 70 to 157 days of gestation (normal gestation averages 164 days) does not interfere with the viability or growth of the placenta until it is spontaneously delivered near the expected due date. No abnormalities in placental shape, size, or histology were commented on in that study. The present

study was carried out to determine whether early removal of the embryo (29th to 34th day of gestation) would cause any morphologic changes in the placenta.

Materials and methods. Seven adult female rhesus monkeys underwent embryectomy at 29 to 34 days of gestation. The onset of gestation was taken as the time the monkeys were housed with the male if serum drawn approximately 3 weeks later showed evidence of chorionic gonadotrophic activity in the mouse uterine weight assay of Klinefelter *et al* (10). Four of the monkeys received no medication and underwent hysterectomy 14 to 36 days following embryectomy. Three others received cortisone (25 mg s.c. daily) and 19-norethisterone (20 mg p.o. daily) and were sacrificed and autopsied 166 to 168 days following embryectomy. The latter time is at least 4 weeks later than the expected duration of gestation for those mating. An outline of the study protocol is included in Table I.

Removal of the embryo was carried out under pentothal anesthesia through a midline lower abdominal incision and a vertical incision in the fundus of the uterus. Care was taken to enter the chorionic cavity in the clear space between the two discs of placental tissue(11). The umbilical cord was cut and the embryo removed. The uterus was then closed in one layer with a continuous cat gut suture.

Results. Viable chorionic villi were found

* Present address: Dept. of Obstetrics and Gynecology, George Washington University Hospital, Washington, D. C.

in 2 of the 4 monkeys whose uteri were removed within 36 days of the embryectomy. In a third there was an area of hyalinization with thrombosed vessels, consistent with a partially involuted placental site. The fourth showed a small abscess formation in the hysterectomy

incision, but the endometrial pattern was that of proliferative phase. There was no evidence of viable trophoblastic tissue. An occasional villous showed hydropic degeneration (Fig. 1), but most had condensed villous stroma along with degenerative changes (Fig. 2). The

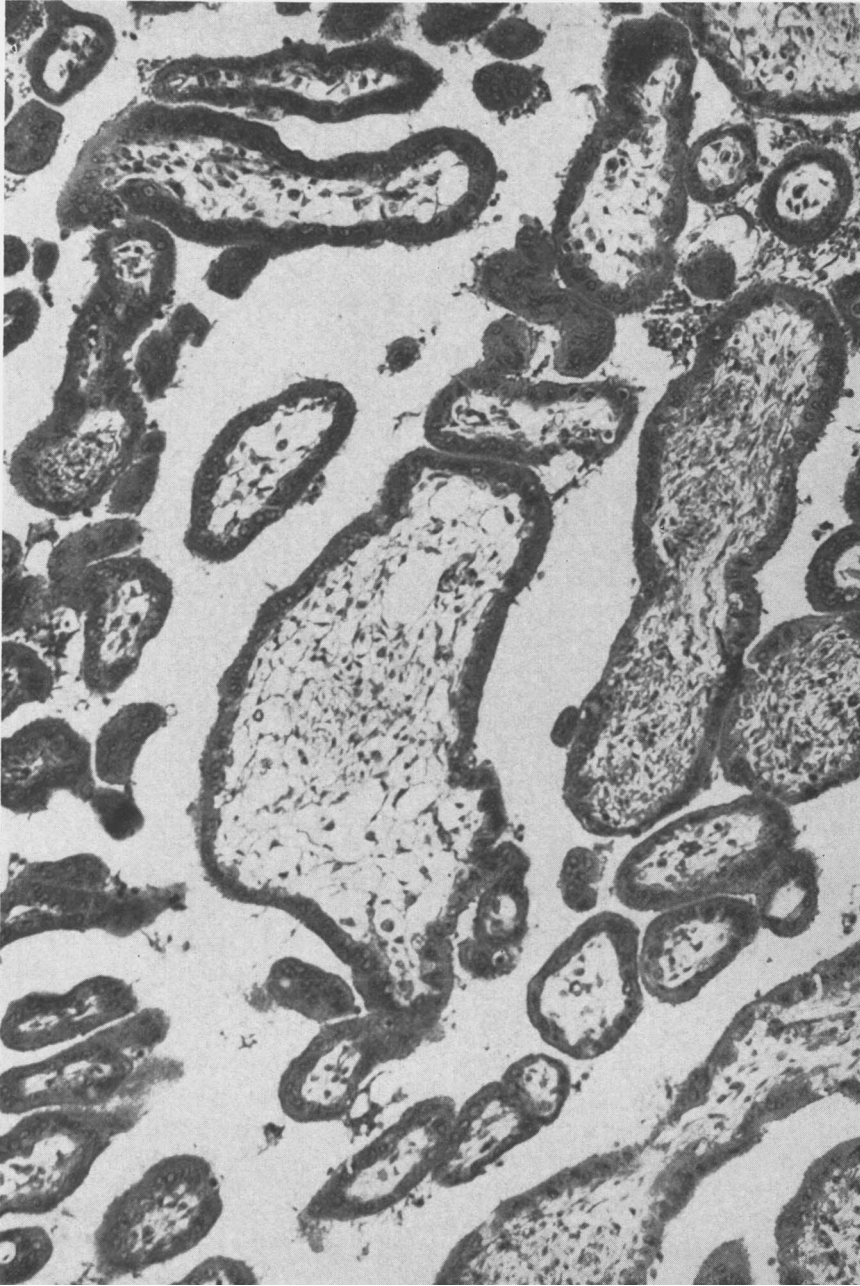


FIG. 1. Chorionic villi removed from uterus of Monkey V-396 22 days following embryectomy. Hematoxylin & eosin stain. Magnification 285 \times .

villous vasculature did not persist. In no sections was there any evidence of proliferative or anaplastic changes in the trophoblastic cells.

The 3 animals carried on long term therapy with cortisone acetate (25 mg s.c. daily) and

19-norethisterone (20 mg p.o. q.d.) showed no persistence of viable chorionic villi when autopsied 166-168 days later. There were profuse decidual changes in all three and two of them had areas of hyalinization which might represent ghost villi, but there was not

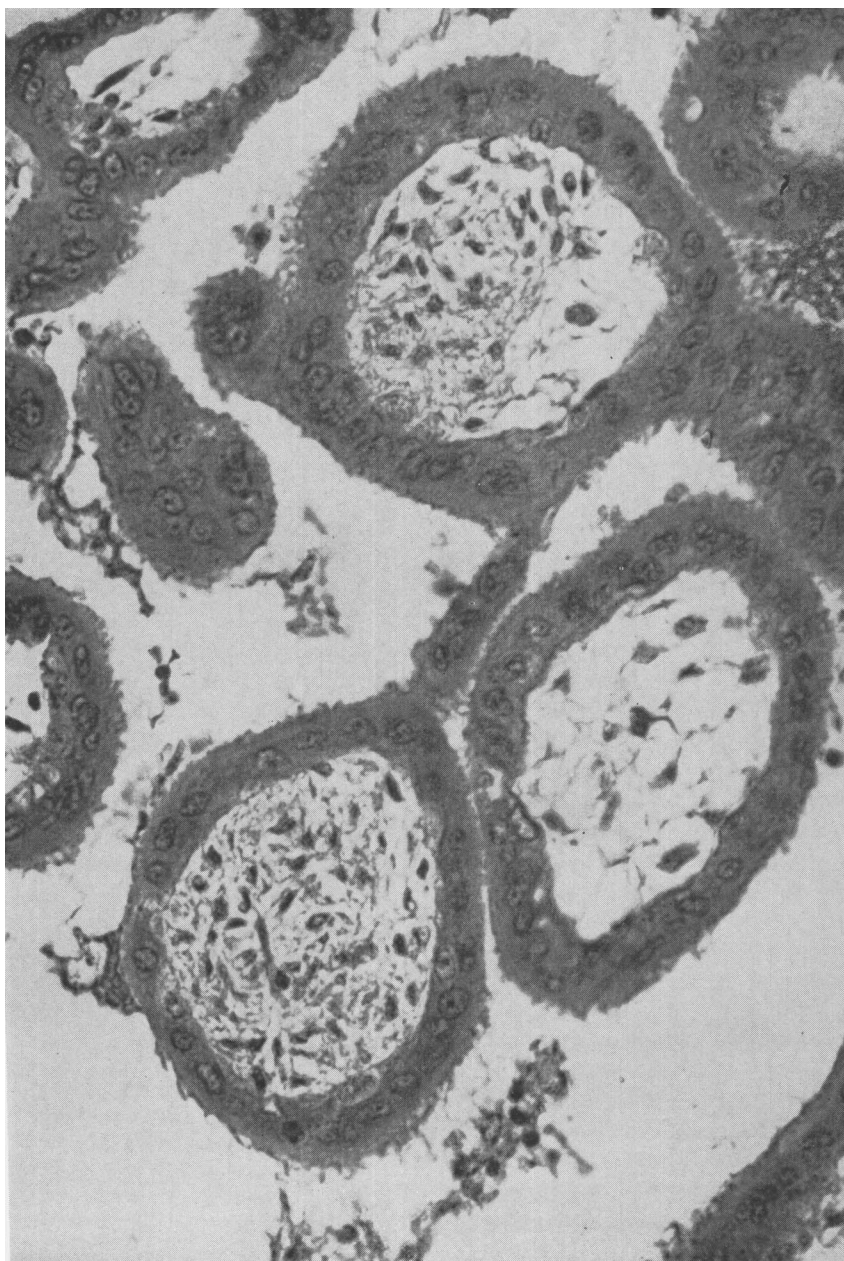


FIG. 2. Chorionic villi removed from uterus of Monkey I-530 14 days following embryectomy. Hematoxylin & eosin stain. Magnification $350\times$.

TABLE I. Study Protocol.

Monkey	Gestational age at embryectomy (days)	Interval before removal of uterus (days)	Medication	Histology
M-396	29	27	None	Prolif. endom. Abscess in hysterotomy incision.
V-396	34	22	"	Viable villi. Some slightly hydropic. No epith. prolif.
I-530	34	14	"	Same as V-396.
J-29	30	36	"	Hyalinized placental site.
X-676	33	168	Cortisone & Norlutin*	Extensive decidual reaction in endometrium.
V-397	29	166	"	Same as X-676 plus areas of hyalinization.
X-846	29	166	"	Same as V-397.

* 25 mg cortisone acetate s.c. q.d.
20 mg 19-norethisterone p.o. q.d.

enough cellular detail to establish this. The lungs of the 3 autopsied animals were examined and no trophoblastic cells were seen. Since none of these 3 monkeys passed tissue at the expected time of delivery, it is assumed that the placental villi underwent necrosis and resorption.

Comments. The presence of biologically active chorionic gonadotropin in monkey serum in pregnancy was utilized to establish the diagnosis of early pregnancy so that the fetus could be removed before the end of the 5th week of gestation. The persistence of viable trophoblast in only 2 of the 7 monkeys studied is in contrast with the findings of Van Wagenen and Newton(9). When they removed the embryos at the 10th to 23rd week of gestation in 12 rhesus monkeys, 11 of the monkeys passed viable placental tissue near the expected time of parturition, 24 weeks. It is considered that the smaller percentage of monkeys showing persistent placental viability in this study is due to removal of the embryo at an earlier stage in pregnancy.

The hypothesis that decreased villous blood flow due to death of the embryo is the cause of the villous swelling which then initiates the formation of a hydatidiform mole has often been proposed. This hypothesis does not account for the association of the hydropic swelling of the villi and proliferation and anaplasia of the trophoblastic cells, a characteristic feature of hydatidiform mole. Although the study reported here fails to support this hypothesis, it has not ruled out the effect of the continued presence of a dead embryo.

Conclusions. 1. Following embryectomy at 19-34 days of gestation in the rhesus monkey, viable trophoblast was present in 2 of 4 of the animals having a hysterectomy within the ensuing 5 weeks. 2. No viable trophoblast was found 5 months after the embryectomy in 3 monkeys treated with cortisone and a progestational agent. 3. The viable villi found in 2 of the 7 monkeys showed absence of villous vasculature and occasional hydropic changes consistent with hydropic degeneration, but there was no evidence of trophoblastic proliferation. 4. No support is given to the hypothesis that early death (or removal) of the embryo is the etiologic factor in the development of the hydatidiform mole.

1. Park, W. W., *Modern Trends in Pathology*, Chap. 10, Disorders of Trophoblast, Butterworth & Co., London.

2. Hertig, A. T., Mansell, H., *Tumors of the Female Sex Organs, Part I. Hydatidiform Mole and Choriocarcinoma*, Armed Forces Inst. of Pathol., 1956, v33, Sect. 9, p7.

3. Delfs, E., *Anat. Rec.*, 1941, v79, (suppl.), 17.

4. Van Wagenen, G., Simpson, H., *Proc. Soc. Exp. Biol. and Med.*, 1955, v90, 346.

5. Tullner, W. W., Hertz, R., *Endocrinology*, 1966, v78, 204.

6. Weymeersch, A., *Ann. Soc. ac. med. natur.*, 1912, v70, 104.

7. Hammond, J., *J. Agri. Sci.*, 1914, v6, 263.

8. Newton, W. H., *J. Physiol.*, 1935, v84, 196.

9. Van Wagenen, G., Newton, W. H., *Am. J. Physiol.*, 1949, v129, 485.

10. Klinefelter, H. F., Jr., Albright, S., Griswold, G. C., *J. Clin. Endocrinol. & Metab.*, 1943, v3, 529.

11. Hartman, C. G., Straus, W. L., Jr., eds.,
Anatomy of the Rhesus Monkey (*Macaca mulatta*),

Williams & Wilkins Co., Baltimore, 1933, p244.
Received August 24, 1966. P.S.E.B.M., 1966, v123.

Inhibition of Spermatogenesis and Ovulation in Rabbits with Antiovine LH Rabbit Serum.* (31610)

S. K. QUADRI,† L. H. HARBERS, AND H. G. SPIES (Introduced by A. V. Nalbandov)
Kansas State University, Manhattan, Kansas

Antiovine LH rabbit serum has been reported to neutralize endogenous gonadotropins in immature and mature rats of both sexes(1,2,3,4). Inhibition of the stimulatory effect of exogenous rat, pig and whale pituitary extracts on the ventral prostate of immature hypophysectomized rats by concurrent administration of antiovine LH sera has likewise been observed(5). Ovulation has been blocked in rats by injecting antiserum between 1:00 and 4:00 PM on the day of proestrus(6). Although the rabbit was utilized for antibody production against tropic hormones, inhibition of endogenous and exogenous gonadotropins in rabbits following active and passive immunization has not been disclosed.

This study examined (1) the effect of active immunization of adult male rabbits to NIH-LH-S₈ and S₁₀ on libido and testes function, (2) neutralization of endogenous LH and exogenous ovine LH in female rabbits given antiovine LH rabbit serum and (3) the duration of antibody persistence in female rabbits following passive immunization.

Materials and methods. Experiment I: Eight 3.5-4.4 kg New Zealand White male rabbits were randomly divided into 4 groups of 2 animals each. Each male was individually caged and trained with the aid of a dummy rabbit to serve an artificial vagina. Eight semen collections from each male at 4-day intervals provided estimates of variability in semen characteristics within and between in-

dividuals prior to experimental treatments.

Controls: Animals in the control group received no additional treatment. Semen collections were continued at 4-day intervals throughout the experimental period.

LH + adjuvant: Each animal received subcutaneously 1.5 mg NIH-LH-S₈ or S₁₀ dissolved in 1.5 ml saline mixed with an equal volume of Freund's complete adjuvant (Difco, Detroit, Mich.) weekly for 4 weeks. Two 2.0 mg booster injections were given 2 weeks apart after the fourth 1.5 mg injection. After an additional lapse of 12 weeks, two additional 2.0 mg booster injections of LH at 2-week intervals were given.

Adjuvant: Animals in the adjuvant control group received injections of Freund's complete adjuvant only as described for the LH + adjuvant group.

LH + adjuvant + testosterone: Each animal in this group was injected with LH + adjuvant as described above. In addition beginning the sixth week after the initial LH + adjuvant injection, 1.0 mg testosterone propionate dissolved in 0.2 cc sesame oil was injected subcutaneously on alternate days for the remainder of the experimental period.

All animals were sacrificed 28 weeks from the beginning of immunization. The testes, epididymides, seminal vesicles, prostate, penis and pituitary glands were weighed and immediately frozen in liquid nitrogen or preserved in 10% formalin for histological evaluation. Samples of each tissue were sectioned at 10 μ and stained with haematoxylin-acid fuchsin or haematoxylin-Mallory's triple stain. Experiment II. Blood from the LH + adjuvant treated males in Exp. I was collected at 3- to 5-day intervals following the 2 booster injections of 2.0 mg LH at 2-week intervals

* This investigation was supported in part by funds provided in Grant HD- 00392 from Nat. Inst. Health. Contribution No. 349 Dept. of Animal Husbandry, Kansas Agri. Exp. Station, Manhattan, Kan.

† Present address: Dept. of Microbiology and Public Health, Michigan State Univ., East Lansing.