

Metachromasia of Epimysial Connective Tissues from Normal and from Pale, Soft, and Exudative Porcine Muscle* (33082)

P. E. McCLAIN,¹ A. M. PEARSON, R. A. FENNELL, AND R. A. MERKEL
(Introduced by B. S. Schweigert)

Departments of Food Science and Zoology,² Michigan State University, East Lansing, Michigan
48823

Ludvigsen (1) first described a condition in swine, which he called "muscle degeneration disease." The muscle is pale, soft, and watery in appearance and has been called "white muscle disease" (2), or more recently has been abbreviated from "pale, soft, and exudative" to "PSE" (3). This condition has been encountered in swine throughout the world and has been estimated to vary from an incidence of 18% of all hogs slaughtered in U. S. (4) to 35–40% in Denmark (5). It is now generally accepted that the PSE condition is associated with an accelerated rate of postmortem glycolysis and an early onset of rigor mortis (6, 7, 8). The sarcoplasmic proteins are severely denatured and exhibit reduced solubility (9, 10).

Although the literature is well documented on the biochemistry, physiology, and histology of PSE muscle tissue, little or no emphasis has been placed upon the connective tissues. However, it has been reported that certain muscles from severely affected PSE pigs have lost most of their intermuscular binding (11), and in some cases the muscles lose their connective tissue attachments and can be easily removed from the carcasses (12). This has been attributed to the combined effects of a low pH and a high temperature for the first few hours after death (approx 36°C), reportedly resulting in thermal shrinkage or hydrolysis of the connective tis-

sue attachments of the muscle to the fatty tissues and bones (11, 12). Therefore, the present study was undertaken to determine if the connective tissues are involved in the PSE condition, and if so to elucidate the changes involved.

Methods. The loins from 6 market weight (liveweight of approximately 86–109 kg) pig carcasses were selected 48 hours after slaughter. The loins were chosen on the basis of subjective visual appearance and the turbidimetric method of Hart (13) so that three represented the normal group and three the PSE group. The epimysium was removed from the anterior end of the *longissimus dorsi* muscle at the third and fourth ribs and dissected free of adhering fat and muscle. Part of each sample was fixed in formalin and stored in 70% ethanol, while the remainder was frozen in liquid nitrogen and stored at –20°C until utilized.

The collagen and elastin fibers were observed histologically utilizing Verhoeff's elastin stain (14), hematoxylin and eosin (15) and Mallory's aniline blue stain (15). The ground substance was studied histochemically utilizing the toluidine blue metachromatic staining technique of Van Alten and Fennell (16) on both fixed and unfixed samples stained at a pH of either 2.2, 5.6, or 8.0.

Light transmittance was measured in arbitrary units using a modified Leitz Dialux microscope equipped with a Vickers Instrument photomultiplier and an automatic integrating exposure unit. All readings were made under identical settings and conditions and are comparable for any single series of measurements.

Results. The typical metachromasia in the epimysial connective tissue from normal muscle stained at pH 5.6 is shown in Fig. 1. In contrast, Fig. 2 illustrates the metachromasia of the epimysium from PSE muscle. The dif-

* Journal article 4340, Michigan Agricultural Experiment Station, East Lansing.

¹ A portion of the research reported in the Ph.D. thesis of the senior author. Present address: Human Nutrition Research Division, USDA, Agricultural Research Service, Beltsville, Maryland 20705.

² This investigation was supported in part by Public Health Service Research Grant No. UI-00191 from the National Center for Urban and Industrial Health, and in part by the Food Research Division, Armour and Company, Oak Brook, Illinois.

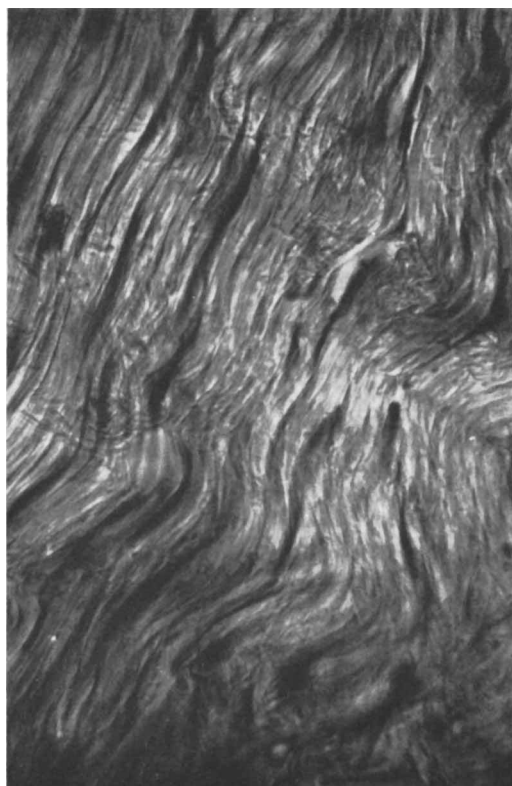


FIG. 1. Metachromasia of normal epimysium stained at pH 5.6.

ferences observed are evident from the data in Table I, which show the light transmittance values in arbitrary units for the PSE and normal tissues stained at both pH 8.0 and 5.6. The light intensity was significantly greater ($p < .01$) at pH 5.6 than at pH 8.0 in both the PSE and normal tissues, which indicates a greater amount of dye uptake at the higher pH. Statistical analysis also revealed that there was a significant interaction ($p < .05$) between pH and the method of fixing. At pH 8.0 the difference in light intensity was small, but at pH 5.6 the fixed samples were notably lighter than the unfixed samples. Regardless of the pH of staining or the method of fixation, there was a significant ($p < .05$) difference in light transmittance values for the normal and PSE connective tissues, with the latter group staining less intensely.

A loss of beta metachromasia was also observed on comparing the same tissue before

and after an alcohol rinse. The reddish-purple color had almost completely reverted to the blue alpha color, indicating that the

TABLE I. Light Transmittance Values for Toluidine Blue Stained Epimysial Connective Tissues.^a

Animal no.	pH 8.0		pH 5.6	
	Fixed	Unfixed	Fixed	Unfixed
PSE				
1	14.50	14.25	14.50	15.75
4	15.50	13.00	19.25	16.00
6	13.00	16.50	18.50	15.50
Mean	14.33	14.58	17.41	16.08
Normal				
2	11.00	10.50	15.50	13.75
3	12.00	11.25	16.25	12.00
5	11.00	12.50	16.90	14.50
Mean	11.33	11.41	16.21	13.41

^a Each value represents an average of three observations on two independent replications.

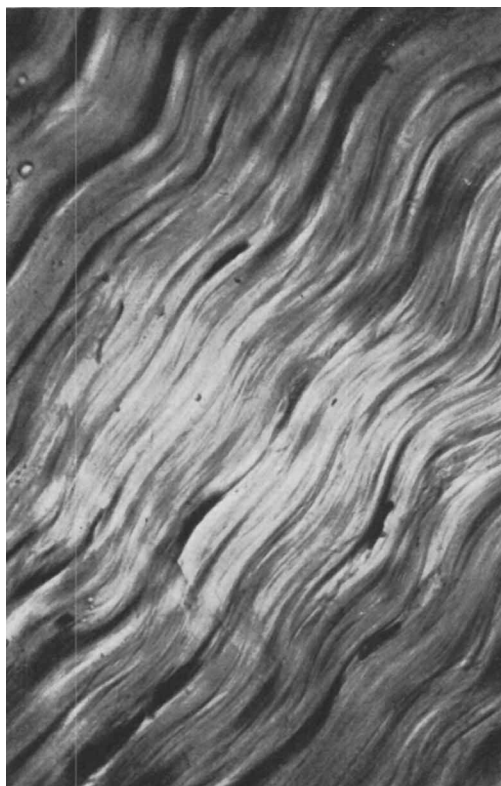


FIG. 2. Metachromasia of PSE epimysium stained at pH 5.6.

dye was largely bound by weakly stable groups.

A comparison of PSE and normal epimysial connective tissue stained with Verhoeff's elastin or with Verhoeff-Van Geisen stain showed no distinctive histological differences in appearance. Although some samples seemed to exhibit a greater amount of cellular activity, as evidenced by a larger number of nuclei, the condition did not appear to differ between the PSE and normal tissues. Thus, results suggest that neither the fibers nor cells differ greatly for the two sources of epimysial connective tissue.

Discussion. According to Pearse (14) toluidine blue metachromasia results from the presence of free electronegative surface charges of a certain minimum density. Increasing charge density results in an increased complexing of the dye. The monomeric or alpha form of the dye results in a blue color. Beta metachromasia is the result of dimer formation and yields a violet or purple color. Due to the bond angle between carboxyl groups, metachromasia due to this group is only weakly stable and can be reversed by washing in alcohol. On the other hand, sulfate ester groups, such as occur in the chondroitin sulfates result in a stable nonreversible metachromasia (14). Szirmai (17) reported that the carboxyl groups, such as are found in hyaluronic acid are unable to bind dye below pH 2.0, while the sulfate groups are almost completely dissociated at this pH. Thus, any dye binding at pH 1-2 is almost entirely due to the sulfate groups. In the present study, dye binding of the porcine epimysium was extremely slight at pH 2.2. Therefore, based upon the metachromatic reversibility on washing with alcohol and an almost nonexistent ability to bind the dye at pH 2.2, the metachromasia observed in porcine epimysial connective tissues was probably not due to chondroitin sulfate.

The greater amount of light transmittance indicates a decreased amount of acid substances or an altered mucopolysaccharide content in the PSE connective tissues. The rapid pH drop at a high temperature could conceivably alter the ground substance and fibrous proteins in much the same way as the

sarcoplasmic proteins are altered by these conditions (18). It is known that rapid formation of lactic acid, resulting in a low pH while the muscle temperature is still high, results in a sharp increase in the amount of free water (11). The dramatic effects of lactic acid upon solubilizing connective tissues are well known (19).

Previous work (20) has indicated that at death all porcine muscles are dark and firm. Several workers (11, 21) have been unable to find any visible evidence of degeneration at the time of death in muscles that ultimately become PSE. However, more recent work has shown that some structural abnormalities occur in both PSE and in dark, firm muscles (22). Similarly, the presence of alkaline and acid phosphatase activity has been reported in porcine muscle (23). This would suggest that in some cases the PSE musculature may exhibit a degenerative condition. Conceivably, this could also help to explain the altered metachromatic staining in the current study.

Summary. The epimysial connective tissues from pigs exhibiting normal or pale, soft, and exudative (PSE) musculature were examined using histological and histochemical techniques. Light intensity values showed that the PSE epimysium had a lower toluidine blue staining intensity than that of normal epimysium, indicating that the ground substance was altered. Histologically, there was no evidence of differences in appearance or fiber types between PSE and normal connective tissues.

1. Ludvigsen, J., Proc. XV Inter. Vet. Congr., Baktryckeri, Stockholm, I, 602 (1953).
2. Kjølberg, D., Manners, D. J., and Lawrie, R. A., Biochem. J. 87, 351 (1963).
3. Forrest, J. C., Judge, M. D., Sink, J. D., Hoekstra, W. G., and Briskey, E. J., J. Food Sci. 31, 13 (1966).
4. Forrest, J. C., Gundlack, R. F., and Briskey, E. J., Proc. Am. Meat Inst. Found. Res. Conf. 15, 81 (1963).
5. Clausen, H. and Thomsen, R. N., Natl. Res. Inst. Animal Husbandry, Copenhagen, Rpt. 317, 1960.
6. Briskey, E. J. and Wismer-Pedersen, J., J. Food Sci. 26, 297 (1961).
7. Briskey, E. J., Sayre, R. N., and Cassens, R.

- G., *J. Food Sci.* **27**, 560 (1962).
8. Kastenschmidt, L. L., Briskey, E. J., and Hoekstra, W. G., *J. Food Sci.* **29**, 210 (1964).
 9. McLoughlin, J. V., *Irish J. Agr. Res.* **2**, 115 (1963).
 10. Sayre, R. N. and Briskey, E. J., *J. Food Sci.* **28**, 675 (1963).
 11. Briskey, E. J., "Proc. Meat Tenderness Symp.," p. 195. Campbell Soup Co., Camden, New Jersey, 1963.
 12. Sayre, R. N., Briskey, E. J., and Hoekstra, W. G., *J. Food Sci.* **28**, 292 (1963).
 13. Hart, P. C., *Tijdschrift Diergeneesk* **86**, 156 (1962).
 14. Pearse, A. G. E., "Histochemistry—Theoretical and Applied." Little, Brown, Boston, Massachusetts, 1960.
 15. Davenport, H. A., "Histological and Histochemical Techniques," Saunders, Philadelphia, Pennsylvania, 1961.
 16. Van Alten, P. S. and Fennell, R. A., *Anat. Record* **127**, 677 (1957).
 17. Szirmai, J. A., *J. Histochem. Cytochem.* **11**, 24 (1963).
 18. Bendall, J. R. and Wismer-Pedersen, J., *J. Food Sci.* **27**, 144 (1962).
 19. Gustavson, K. H., "The Chemistry and Reactivity of Collagen," Academic Press, New York, 1960.
 20. Briskey, E. J., Bray, R. W., Hoekstra, W. G., Phillips, P. H., and Grummer, R. H., *J. Animal Sci.* **18**, 146 (1959).
 21. Cassens, R. G., Briskey, E. J., and Hoekstra, W. G., *Nature* **197**, 1119 (1963).
 22. Briskey, E. J., *Advan. Food Res.* **13**, 89 (1964).
 23. Bodwell, C. E., Pearson, A. M., and Fennell, R. A., *J. Food Sci.* **30**, 944 (1965).

Received Feb. 29, 1968. P.S.E.B.M., 1968, Vol. 128.

Copper Loading in the Turkey* (33083)

R E. Wiederanders (Introduced by B. DeBoer)

Harmon Park Research Laboratory, Williston, North Dakota 58801; and Department of Physiology and Pharmacology, School of Medicine, University of North Dakota, Grand Forks 58201

Decreased serum ceruloplasmin accompanies hepatolenticular degeneration (Wilson's disease). This deficiency may play a role in the pathogenesis by allowing excess deposition of tissue copper (1). It was thought that an animal lacking ceruloplasmin might respond to copper loading by developing the symptoms of Wilson's disease. The broad-breasted white turkey gave promise of serving as an experimental model (2); it has no measurable ceruloplasmin oxidase activity and has the lowest reported plasma copper levels (3).

Materials and Methods. Thirty-nine turkeys of the broad-breasted white strain were fed starting ration for 6 weeks and then maintained an oats, barley, and water *ad libitum*. Copper sulfate pentahydrate, dissolved in distilled water to a Cu concentration of 1 mg/ml, was injected subcutaneously daily beginning at age 91 days. Group I

received 0.5 mg of Cu for 7 days; group 2, 0.5 mg for 90 days; group 3, 0.5 mg for 84 days, then 5.0 mg for 17 days. Samples of blood, liver, brain, kidney, and muscle of experimental and control birds were taken at the time of sacrifice. The blood was heparinized and centrifuged; plasma ceruloplasmin oxidase activity was determined by the method of Houchin (4). Values are reported as units of optical density (Coleman junior spectrophotometer) because a conversion factor to mg of ceruloplasmin is not available for the turkey. Fresh tissue samples were weighed to the nearest mg. Tissue and plasma Cu were determined by the wet ash method (5). Significance of data was determined by the student *t* test.

Results. No symptoms suggestive of hepatolenticular degeneration were observed. Experimental birds of groups 1 and 2 appeared as healthy as controls. About 3 days prior to autopsy, copper-injected group 3 birds were observed to have diarrhea and appeared pale with ruffled feathers. This presumably was

* This work was aided by a grant from the National Foundation—March of Dimes.