

## Experimental Autoallergic Orchitis in Rhesus Monkeys\* (33729)

JUAN A. ANDRADA,<sup>1</sup> ENIA C. ANDRADA, AND ERNEST WITEBSKY<sup>1</sup>

*The Center for Immunology and Department of Microbiology, School of Medicine,  
State University of New York at Buffalo, Buffalo, New York 14214*

Experimental orchitis was first produced by Voisin *et al.* (1951) by iso- and auto-sensitization in guinea pigs (1), by Freund *et al.* (1954) in rats (2), and by Pokorna *et al.* (1963) in mice (3). Recently, Mancini, Andrada *et al.* (1965) were able to produce allergic orchitis in man (4). A group of four volunteer patients suffering from prostatic carcinoma was studied. Each of the four patients was immunized prior to surgical castration with testicular suspensions (autoimmunization and isoimmunization). After a period of 3–8 weeks, two of the four patients developed patchy lesions in the contralateral testis consisting of congestion, serous edema and sloughing of germinal cells. Low titered circulating antibodies also appeared. To obtain a model for autoallergic orchitis closely related to man, an attempt was made to induce autoallergic orchitis in monkeys.

**Materials and Methods. Animals.** Eight adult male rhesus monkeys (*Macaca mulatta*) 5 years of age or older and weighing 15–20 lb were selected for these experiments. They were unilaterally orchietomized (hemicastrated) and blood specimens were obtained. The histological picture of the testis was normal from all animals except one (Monkey no. 4) which presented arrest of spermatogenesis in about 50% of the tubules.

**Tissue extracts.** The testicular material obtained from each experimental animal at the time of hemicastration, if not used immediately, was preserved at  $-40^{\circ}$ . The glands were trimmed, washed in cold buffered saline, cut up and homogenized for 5 min in phosphate buffered saline, pH 7.2, by means of a Teflon homogenizer. Two ml of saline was

used for each gram of tissue. Each preparation was ultrasonicated for 5 min at 20,000 cps in an MSE Mullard disintegrator, kept overnight in the cold room under constant stirring, and then centrifuged at 3000 rpm in a refrigerated centrifuge for 20 min. The supernatant provided a fine suspension with a final protein concentration of approximately 3.5 mg/100 ml.

**Mode of injection.** One ml of the suspension was emulsified with an equal volume of complete Freund adjuvant and 0.1 ml was injected intradermally into 6 sites in each inner thigh; thus each animal received 1.2 ml of the mixture. Second and third injections were given into the interdigital regions of both feet.

**Schedule of injections.** The first group consisted of 5 animals, 4 of which (Monkeys nos. 1, 2, 7, and 8) received one injection of the testicular material. Testis of Monkey no. 2 was used for immunization of both Monkey no. 1 and Monkey no. 2, and testis of Monkey no. 7 was used to immunize Monkey no. 7 and Monkey no. 8. Consequently two monkeys (nos. 2 and 7) of this group were autoimmunized and two (nos. 1 and 8) were isoimmunized. Biopsies were obtained between days 40 and 104. The fifth monkey (no. 3) was injected with liver extract in complete Freund adjuvant according to the same schedule, and served as a control for this group.

The second group consisted of 3 animals (Monkeys nos. 4, 5, 6) each of which received two injections with a 39-day interval between injections. Monkey no. 4 (oligospermic animal) had only one biopsy (castration) at day 71 and Monkey no. 5 had biopsies at days 46 and 91 (castration). As control for this group, Monkey no. 6 was injected in the same manner with saline solution in complete Freund adjuvant.

**Histological examination.** Testicular biop-

\*Supported in part by The Population Council, New York, Grant No. M68.77, and in part by U. S. Public Health Service Research Grant CA-02357 from the National Cancer Institute.

<sup>1</sup>Dr. Henry C. and Bertha H. Buswell Research Fellow.

sies were performed by the technique of Charny and Meranze (5). Care was taken to perform the second biopsy in one gland in a place opposite the previous one, to avoid possible detrimental effects of multiple trauma (6). Tissue, including albuginea, was divided into two fragments: a small one fixed in 5% glutaraldehyde solution for electronmicroscopy and the other fixed in 10% buffered formaldehyde for histology. Sections were cut at 6  $\mu$  after paraffin embedding and stained by hematoxylin and eosin and by periodic acid-Schiff reagent.

*Sperm count.* Semen was obtained from most of the monkeys under Nembutal anesthesia using an electro-ejaculator (7); the volume of ejaculate and the number and motility of spermatozoa was studied in the experimental and control animals. Normal monkeys have about 50,000,000 sperms/ml.

*Serologic tests.* Complement fixation tests were performed following the microtechnique of Blizzard *et al.* (8). The extract was diluted 1:100 after centrifugation at 57,000g for 30 min. Guinea pig complement was diluted 1:20.

For the tanned cell hemagglutination tests, the microversion of the technique described in this laboratory was used (9). Antigen was used at 1:100 dilution.

Indirect immunofluorescence tests were performed using 4  $\mu$  thick tissue sections fixed for 2 min in cold acetone. Monkey sera were tested at dilution of 1:5 to 1:40; after an incubation period of 30 min at room temperature in a moist chamber, the sections were washed in buffered saline for 60 min and then treated with a rabbit antiserum against human gamma G globulin conjugated with fluorescein isothiocyanate. Slides were then washed for another 60 min, mounted in glycerol, and observed under a fluorescent microscope.

*Results. Histological studies.* The first experimental group consisting of 4 rhesus monkeys (nos. 1, 2, 7, 8) received one injection of monkey testicular extract incorporated in complete Freund adjuvant.

The sections of the testicles removed from the monkeys before the experiment started

(when all monkeys were initially unilaterally orchiectomized) revealed normal architecture, as illustrated in Fig. 1.

Biopsy taken from Monkey no. 2 at day 40 was normal; biopsy taken from Monkey no. 1 at day 64 showed a few damaged tubules (+ lesion). Biopsies performed later, between days 71 and 89 after injection, showed severe damage in both animals (++++ lesion). Monkeys nos. 7 and 8 had normal testicular biopsies before stimulation and ++ damage at day 70<sup>1</sup>.

Varying degrees of spermatogenic arrest, vacuolization of Sertoli cells and progressive sloughing of germinal cells were observed in 80% of seminiferous tubules (Fig. 2). Some affected tubules had a foamy aspect produced by the numerous vacuoles of the cytoplasm of Sertoli cells; they had no spermatozoa or spermatid and primary or secondary spermatocytes were disintegrating; they also presented thickening of the basement membranes, shown by PAS staining (Fig. 3).

The intertubular connective tissue showed congestion of vessels and diffuse serous edema resulting in a wider separation of the tubules. Some mononuclear cells were present, mostly in Monkey no. 2, infiltrating spaces and surrounding Leydig cells which seemed unaffected.

The relationship of the severity of damage and the sperm count is shown in Table I. As shown, no sperm cells were found in Monkeys nos. 1 and 2 in which 80% of the tubules were damaged. The other two monkeys, nos. 7 and 8, showed damage in 60-75% of the tubules; only a few sperm cells were found. The histological examination of the epididymis of these monkeys showed most of the ducts filled with desquamated spermatocytes and spermatids and very few spermatozoa; many of these cells were degenerated.

<sup>1</sup> In evaluating the severity of the damage, the following scheme was used: +++++, degeneration with complete absence of spermatozoa, spermatids, and spermatocytes; +++, few tubules only showed presence of spermatozoa, spermatids, and spermatocytes; ++, half of tubules showed presence of spermatozoa, spermatids, and spermatocytes; and +, most (80-90%) tubules showed presence of spermatozoa, spermatids, and spermatocytes.

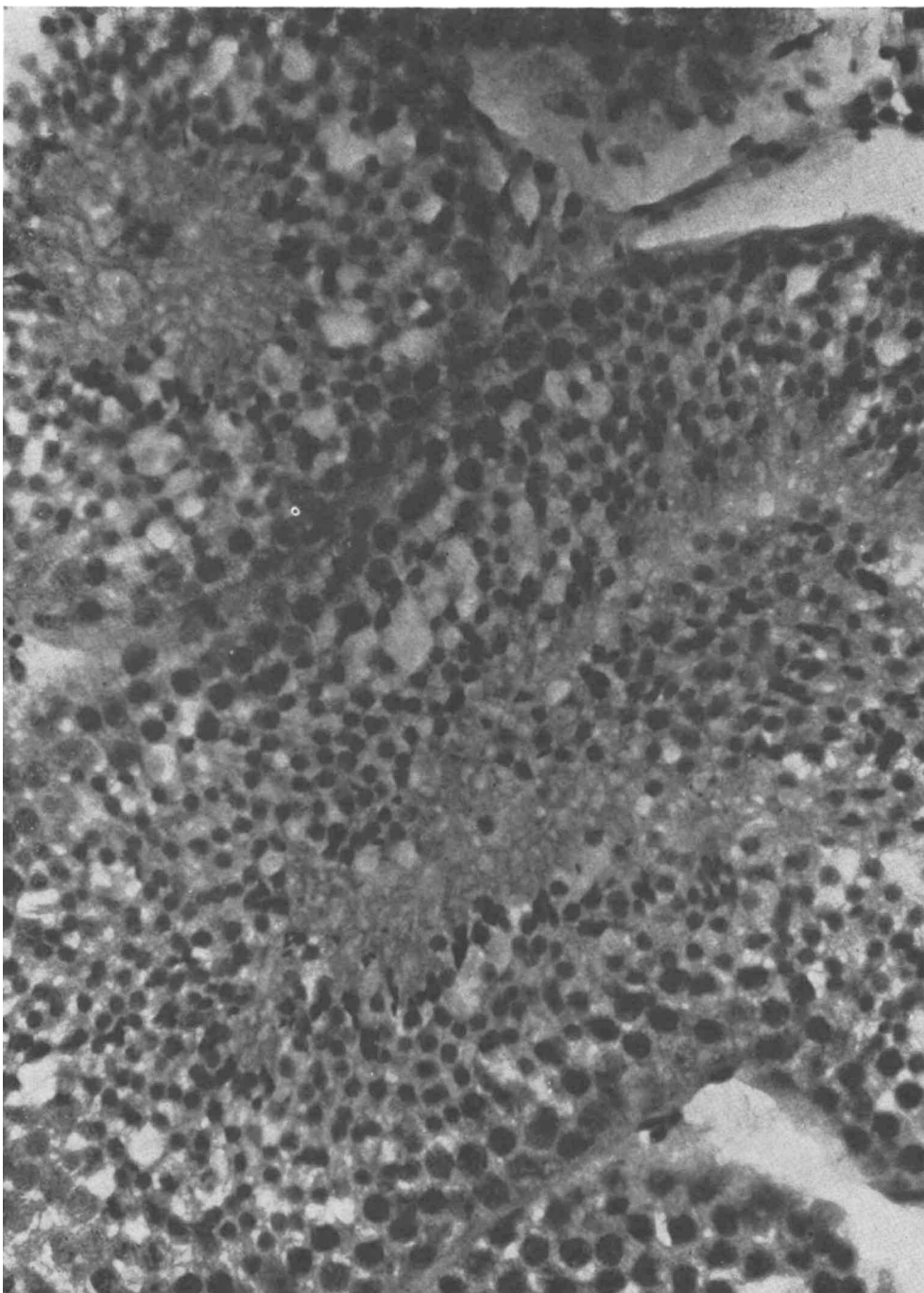


FIG. 1. Testicular biopsy of Monkey no. 1 before immunization: normal seminiferous tubules and elements of the intertubular spaces; the tubules contain a well developed germinal epithelium; H and E stain;  $\times 250$ .

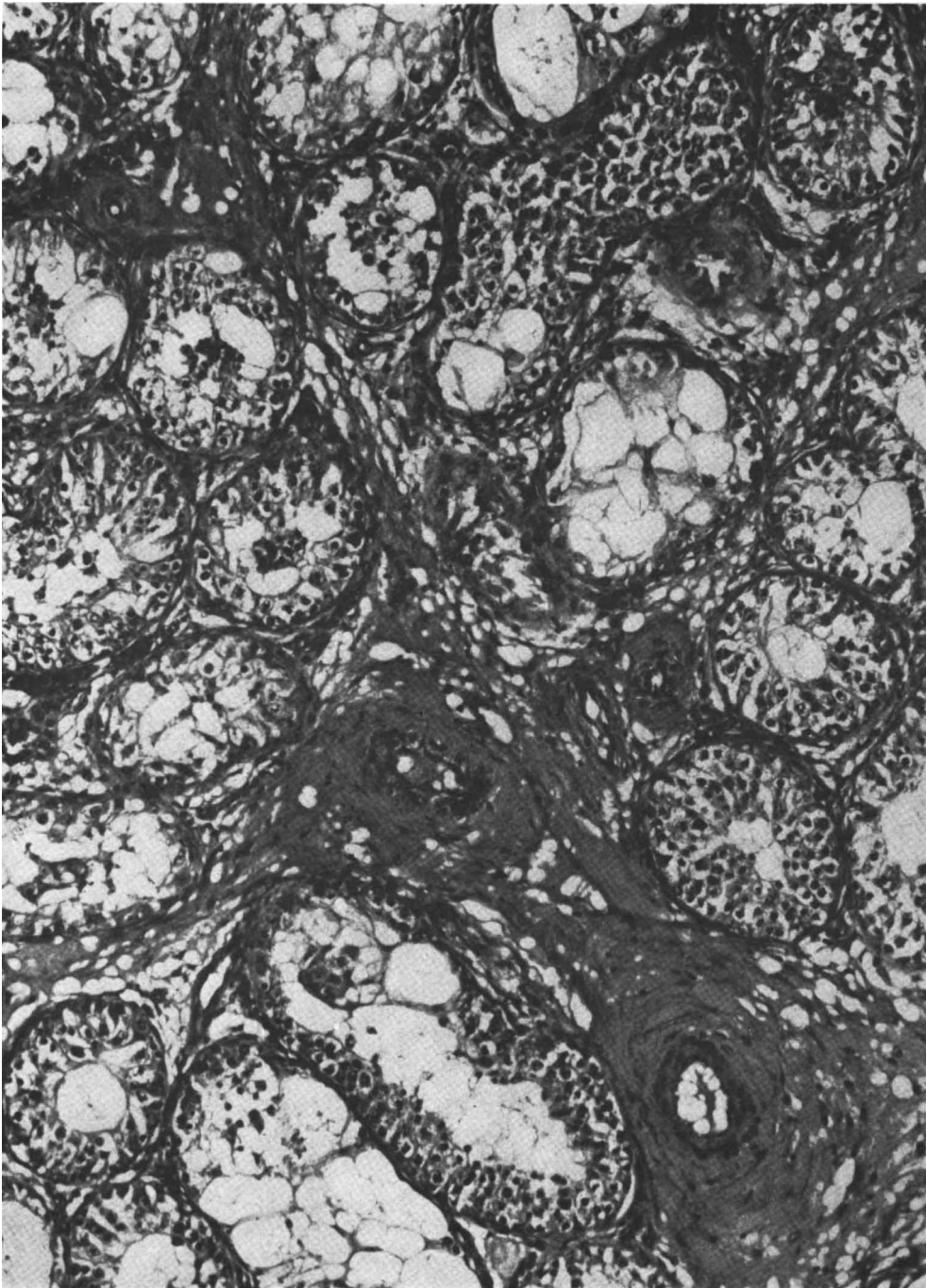


FIG. 2. Testicular biopsy of Monkey no. 2, 89 days after one injection of testicular extract in complete Freund adjuvant: seminiferous tubules show variable degrees of arrest of spermatogenesis; many cells are disintegrating and numerous vacuoles can be observed in the tubules; Intertubular spaces are wider and filled with a plasma-like substance; Leydig cells and some infiltrating lymphocytes are present; H and E stain;  $\times 100$ .

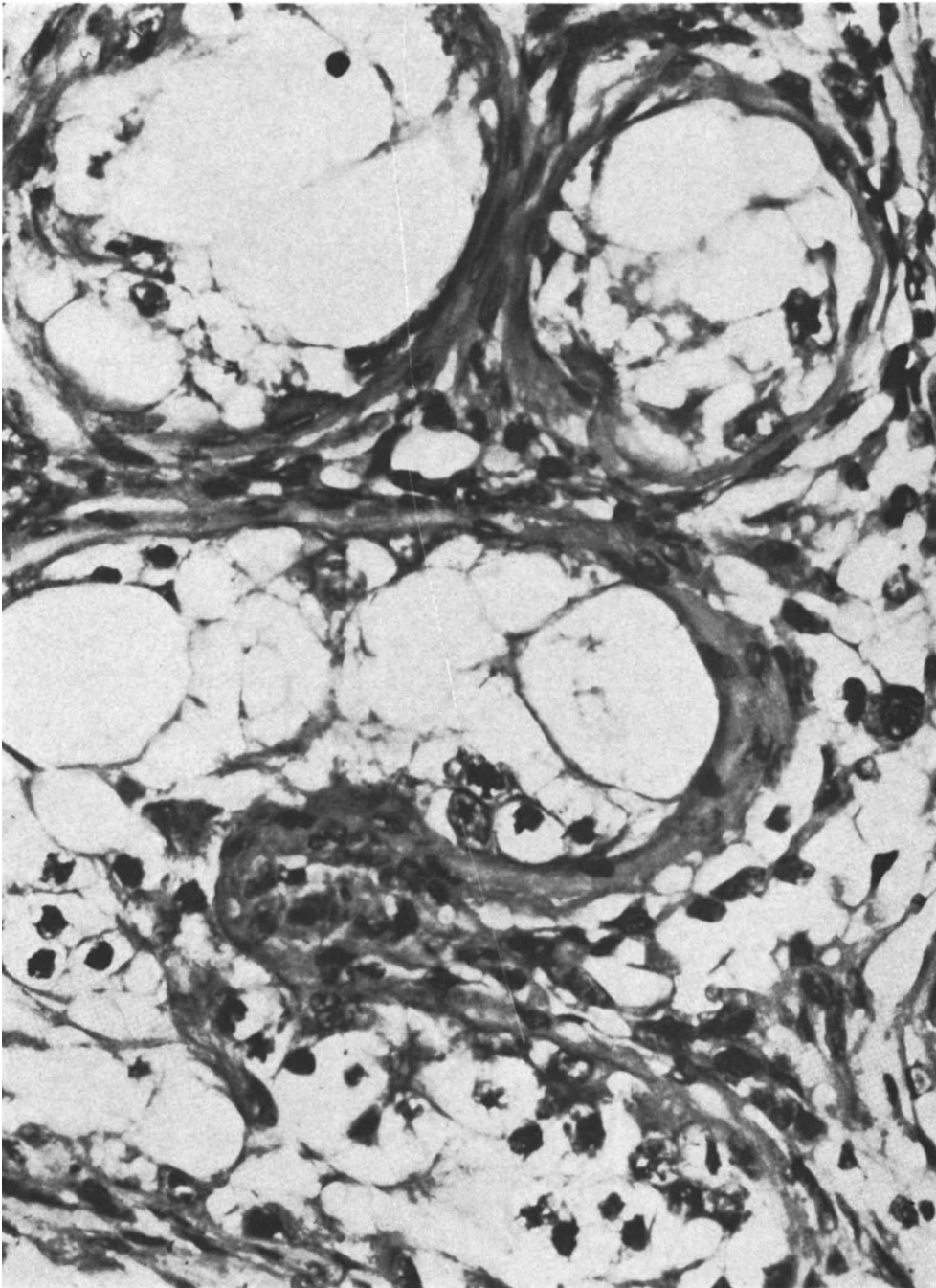


FIG. 3. Testicular biopsy of Monkey no. 1, 74 days after one injection of testicular extract in complete Freund adjuvant: tubules show the lack of germinal cells, the lumen filled with big vacuoles and the thickening of the walls; in the intertubular tissue are many Leydig cells and lymphocytes; PAS stain;  $\times 400$ .

TABLE I. Rhesus Monkeys Immunized with Testicular Extract and Freund Adjuvant.<sup>a</sup>

Monkey no.	Type of immunization	Testicular damage 10-12 weeks after injection		
		Tubules damaged (%)	Severity of damage	Sperm <sup>b</sup> count
1	Iso	80	+++	0
2	Auto	80	+++	0
7	Auto	60	++	5
8	Iso	75	++	0.5

<sup>a</sup> Results obtained after one injection.

<sup>b</sup> Spermatozoa in millions per ml.

A fifth monkey (no. 3) was immunized, following the same schedule, with liver extract plus complete Freund adjuvant; the testicular biopsy obtained 88 days after immunization showed the same normal histological picture as did the biopsy taken before immunization.

The second experimental group included two monkeys (nos. 4 and 5). However, as previously stated, biopsy of Monkey no. 4, taken before the injections were given, already exhibited a histological picture of arrest of spermatogenesis in about 50% of the tubules; sperm count showed decreased number of cells (30 million). The other monkey (no. 5) exhibited a normal picture before immunization. These two monkeys received two injections of the testicular material; the injections were separated by a 39-day interval. On day 71, the oligospermic monkey no. 4) was castrated and showed upon histological examination a marked atrophy of the remaining testis (++++ lesion). Most of the tubules were empty, exhibiting a thickening wall; the intertubular connective tissue was in part invaded by collagen fibers and very few mononuclear cells. The number of sperm cells found in the seminal fluid had decreased to 2000/ml.

The second monkey (no. 5) was castrated on day 91 and histological examination revealed atrophy of the remaining testis (+++ lesion) with intense fibrosis in the tubular wall and the intertubular tissues. The number of spermatozoa went down to 5 mil-

lion/ml. Monkey no. 6 (control) received saline in complete Freund adjuvant following the same scheme of sensitization. A biopsy performed on day 90 did not reveal abnormalities in the testis; also, the number of spermatozoa was not substantially altered.

In all monkeys of this series sacrificed at the conclusion of the experiments, the histological examination of the liver, kidney, thyroid, and adrenals removed at autopsy failed to reveal any abnormalities in these organs. These studies were done to determine the organ specificity of the orchitis observed in monkeys injected with testicular extract in Freund adjuvant. On the other hand, in parallel investigations, testes of monkeys immunized with adrenals, thyroid, and gastric mucosa extracts incorporated into the same adjuvant were examined, and no signs of infiltration, vacuolization or sloughing of spermatid cells were found.

*Serologic tests.* No or very little evidence for the presence of antibodies against testicular tissue was found during the period of immunization of the monkeys described. However, following castration, both Monkeys nos. 4 and 5 were reinjected (third injection) with testicular material incorporated in Freund adjuvants, as described previously. Testicular antibodies appeared, though in relatively low titer, starting at day 9 as demonstrated by complement fixation and at day 19 by tanned cell hemagglutination. These results might be interpreted as due to the removal of the target tissue which served as sort of a sponge in absorbing the circulating antibodies.

In order to study the organ specificity of the antibody response observed, the sera of monkeys injected with various human organ suspensions were tested by means of immunofluorescence. Serum of Monkey no. 5 proved to be useful for immunofluorescent testing. In addition, the serum of a patient suffering from Addison's disease which in previous studies had been found to stain adrenal cortex as well as to cross react with the Leydig cells of the testis were included. The results are shown in Table II. As shown in Table II, the outstanding specificity of or-

TABLE II. Tissue Specificity of Immunofluorescence with Selected Monkey Antisera to Monkey Testis, Adrenal, and Thyroid.

Antisera from monkeys immunized with	Immunofluorescence with sections of monkey:			
	Testis	Adrenal	Thyroid	Others <sup>a</sup>
Testis	+++ <sup>b</sup>	Neg	Neg	Neg
Adrenal	Neg	++	Neg	Neg
Thyroid	Neg	Neg	+++	Neg
Normal monkey serum	Neg	Neg	Neg	Neg
Addisonian human serum	++ <sup>c</sup>	+++	Neg	Neg

<sup>a</sup> Liver, pancreas, heart, kidney.

<sup>b</sup> Staining of germinal epithelium but not interstitium.

<sup>c</sup> Leydig cells only.

gan-specific autoantibodies becomes apparent. It should be added that the serum of the patient with Addison's disease reacted only with the intertubular cells of the testes and not with the germinal epithelium.

*Discussion.* Rhesus monkeys, following the injection of monkey testicular material incorporated in complete Freund adjuvant, developed definite histological alterations in their testicular tissue. Both auto- and isostimulation was successful in all injected animals. Since all animals under investigation were hemi-orchietomized prior to immunization, each animal's own testis served as the control. Conspicuous testicular lesions were prominent between 10 and 13 weeks and consisted of congestion and serous edema accompanied by sloughing of germinal cells. Lymphocytic infiltration was only moderate in one animal (no. 2). Biopsies taken at more frequent intervals might have revealed more evidence for cellular infiltration. However, we did not wish to cloud the results by too many biopsies during the period of immunization. There seemed to be little damage of Leydig cells.

The testicular lesions which were accompanied by a decreased number of spermatozoa in the seminal fluid were very similar to those observed in the human experiments (no. 4). The apparent lack of mononuclear infiltrates also noticed by other authors (10, 11) seem to be a distinctive characteristic of this autoimmune disease. The monkey which presented arrest of spermatogenesis before immunization also developed atrophy and

fibrosis of testes following immunization. As far as immunofluorescence is concerned, the germinal epithelium but not the interstitium gave a positive staining reaction.

*Summary.* Rhesus monkeys were injected with monkey testicular extract incorporated into Freund adjuvant. All six monkeys developed a histological picture of orchitis. The testicular lesions consisted of congestion and serous edema, with sloughing of germinal cells from the tubules; these cells appeared to fill the epididymis ducts. Lesions were more pronounced between 10 and 13 weeks after immunization. Lymphocytic infiltration was present in moderate intensity in only one animal. Circulating antibodies were detected in a few animals at very low titer; however, following castration the titers increased. The organ specificity of the antibody response could be well documented by means of immunofluorescence. According to the results obtained, auto- as well as isosensitization of rhesus monkeys with monkey testicular material incorporated into complete Freund adjuvant produces histological and serological changes very similar to those seen in human experimental orchitis.

1. Voisin, G., Delaunay, A., and Barber, M., *Ann. Inst. Pasteur* **81**, 48 (1951).

2. Freund, J., Lipton, M. M., and Thompson, G. E., *Proc. Soc. Exptl. Biol. Med.* **87**, 408 (1954).

3. Pokorna, Z., Vojtiskova, M., Rychlikova, M., and Chutna, J., *Folia Biol. (Prague)* **9**, 203 (1963).

4. Mancini, R. E., Andrada, J. A., Saraceni, D., Bachmann, A. E., Lavieri, J. C., and Nemirovsky, M., *J. Clin. Endocrinol. Metab.* **25**, 859 (1965).

5. Charny, C. W. and Meranze, D. M., *Surg.*

Gynecol. Obstet. 74, 836 (1942).

6. Gordon, D. L., Barr, A. B., Herrige, J. E., and Paulsen, C. A., *Fertility Sterility* 16, 522 (1965).

7. Lang, C. M., *Lab. Animal Care* 17, 218 (1967).

8. Blizzard, R. M. and Kyle, M., *J. Clin. Invest.* 42, 1653 (1963).

9. Witebsky, E., Rose, N. R., Paine, J. R., and Egan, R. W., *Ann. N.Y. Acad. Sci.* 69, 669 (1957).

10. Brown, P. C., Glynn, L. E., and Holborow, E. J., *J. Pathol. Bacteriol.* 86, 505 (1963).

11. Bishop, D. W., Narbaitz, R., and Lessof, M., *Develop. Biol.* 3, 444 (1961).

Received Oct. 28, 1968. P.S.E.B.M., 1969, Vol. 130.

## Effect of Exogenous Androgen on the Steelman-Pohley Assay for Follicle Stimulating Hormone\* (33730)

DONALD C. JOHNSON AND REHAN H. NAQVI<sup>1</sup>  
(Introduced by E. B. Brown, Jr.)

*Departments of Obstetrics and Gynecology and Physiology, University of Kansas Medical Center, Kansas City, Kansas 66103*

The most widely used assay for follicle stimulating hormone (FSH) is the ovarian weight method of Steelman and Pohley (1). In this assay the effect of endogenously released luteinizing hormone (LH), or LH contained in the test material, is overridden by an excess of human chorionic gonadotropin (HCG), used to augment the action of FSH on the ovary. However, other pituitary hormones, particularly FSH, of the assay animal obviously play a role in the response since hypophysectomized animals are much less sensitive than intact animals. The major inadequacy of the assay is its lack of sensitivity. The lower portion of the dose-response curve has a shallow slope which differs from the steep slope of the most usable portion of the curve (2). If a single slope could be obtained, materials with very low FSH potency, such as plasma, might be assayed more reliably.

The objective of the present study was to partially inhibit the output of endogenous pituitary FSH in order to decrease the ovarian weight obtained with low doses of exogenous FSH. It was hoped that a linear dose-response curve, with a significant slope could thus be obtained. Since estrogen affects the response to HCG in intact animals (3)

by direct and indirect actions, an androgen, testosterone propionate (TP) was chosen for the study. The results demonstrate that the slope was changed by the androgen, but the direction was opposite to that expected.

*Materials and Methods.* Holtzman strain female rats, housed in air-conditioned and light controlled (14 hr light/day) quarters and given free access to water and Purina laboratory chow were used. In each assay, animals were assigned randomly to treatment groups (usually 5-6/group) when 25 days old. The standard FSH (NIH-FSH-S4 was a gift of the Endocrinology Study Section of the NIH) was dissolved in normal saline and given twice daily for 3 days. The total volume given each animal (1.5 ml) also contained 50 IU of human chorionic gonadotropin (HCG). When steroids were used they were dissolved in sesame oil and administered subcutaneously. In some assays, the control animals were given oil 24 or 48 hr prior to, or during, the assay period, but since the results of these trials were in no way different from saline injected animals the data were combined.

In two assays animals were hypophysectomized prior to the beginning of the assay. At the time of hypophysectomy 0.25 mg of cortisone acetate (aqueous suspension) was given each animal, and during the assay a 5% solution of glucose was substituted for drink-

\* Supported by a grant from the NIH.

<sup>1</sup> Postdoctorate fellow of the Ford Foundation.