

Neoplastic Sequelae Following Subcutaneous Implantation of Mice with Rare Earth Metals¹ (35067)

ROGER A. BALL, G. VAN Gelder, J. W. GREEN, JR., AND W. O. REECE
(Introduced by Melvin J. Swenson)

*Veterinary Medical Research Institute, Department of Veterinary Physiology and Pharmacology,
Iowa State University, Ames, Iowa 50010; and the Department of Pathology,
Iowa Methodist Hospital, Des Moines, Iowa 50300*

It has been reported that the rare earths, either as chlorides or in elemental form, are injurious when injected into the skin or subcutis (1, 2). Members of this chemical group also share the ability to cause conjunctivitis (3), and Grant and Kern were able to produce corneal opacities experimentally, provided the epithelium was removed prior to exposure to various rare earth metals (4).

The increased industrial and research use of these elements, as well as their importance as by-products of atomic fission, makes it important to learn more about their toxic potential, since information in this area is scant. This report describes the appearance of sarcomas at the site of subcutaneous implantation of the rare earth metals gadolinium and ytterbium in mice.

Materials and Methods. The gadolinium and ytterbium pellets were obtained from the Institute for Atomic Research, Ames Laboratory, in the form of smooth surfaced pure metal spheres (1.5–2.0-mm diam; 200 mg wt).

Test animals. The mice used for implantations were weanling CFW Albino mice fed a commercial diet (Lab-Blox, Allied Mills, Inc.).

Implantation. Subcutaneous implantations were performed as follows: Under ether anesthesia, an area (1.5 cm²) over the left hip was clipped and scrubbed with a 1:100 solution of benzalkonium chloride. A blunt trocar loaded with a pellet of either gadolinium or ytterbium metal was inserted through

a skin incision in an anterior-dorsal direction, and across the midline, so that the pellet was deposited immediately dorsal to the right scapula. This procedure minimized backward migration of the pellet through the injection tract. The control mice were sham-injected. The numbers of mice receiving either gadolinium or ytterbium were grouped according to sex, and are shown along with the controls, in Table I.

Conventional histopathologic procedures were followed at necropsy, and Gomori's trichrome stain (5) was used to verify impressions based on hematoxylin and eosin-stained sections. The presumptive histologic identification of rare earth metal in the tissues was verified by chemical determinations using the arsenazo method described by Fritz *et al.* (6).

Results. Of 60 rare-earth implanted female mice, 4 developed sarcomas at the metal implantation site. Two of these sarcomas metastasized to the lungs. Twenty-four additional neoplasms were also diagnosed in this group, 22 of which were not associated with the implantation site. Histologically, 16 of the 24 neoplasms were diagnosed as mammary carcinomas. None of the 31 sham-injected female controls developed sarcomas at the injection site or elsewhere. However, neoplasms were frequent in tissues other than at the sham-injection site, with 13 out of a total of 24 diagnosed as mammary carcinomas. In the males, 8 of 58 mice developed sarcomas at the metal implantation site. Pulmonary metastases occurred in 2 males. In addition, 12 of these males developed neoplasms in tissues other than at the implanta-

¹ Supported by Atomic Energy Commission, Division of Biology and Medicine, Contract AT(11-1) 1170.

TABLE I. Neoplasms and Granulomas Developing in CFW Mice Implanted with Gadolinium and Ytterbium.

No. of mice	Sex	Av life span (months)	No. of metal assoc. sarcomas	No. which metastasized	No. of spontaneous neoplasms	Incidence of implantation granulomas
Gadolinium-implanted mice						
30	F	13.3	1	0	15	18/30
30	M	13.9	2	0	5	15/30
Sham-implanted (controls)						
16	F	15.3	0	—	13	—
16	M	15.6	0	—	4	—
Ytterbium-implanted mice						
30	F	16.1	3 ^a	2	9	12/30
28	M	13.1	6 ^b	2	7	12/28
Sham-implanted (controls)						
15	F	9.7	0	—	8	—
16	M	14.6	0	—	6	—

^a Two additional malignant neoplasms involved both the mammary gland and adjacent implantation site and were classified histologically as mammary gland adenocarcinomas. It was felt that they probably were spontaneous.

^b One additional tumor at the implantation site was classified histologically as a relatively benign fibroma. It may or may not have been associated with the rare earth metal.

tion site, most of which were bronchial adenomas. Of 32 control males, 10 developed neoplasms, with bronchial adenomas again most frequent. Approximately one-half of the implanted mice which did not develop sarcomas at the site of metal deposition had histological evidence of a foreign-body granulomatous reaction around the rare-earth metal residue (Table I).

Histologically, 9 of the sarcomas which developed at the implantation site had a pattern characteristic of a fibrosarcoma (Fig. 1). Two had features which suggested possible leiomyosarcomas, and one was diagnosed as an osteogenic sarcoma. In every case, metal-containing macrophages could readily be visualized, either well within the tumor, or in its periphery, or both (Fig. 2). The histological diagnoses for the spontaneous (presumably nonrare-earth associated) neoplasms are given in Table II.

Exact latency periods cannot be given for the various neoplasms. The time lapse between metal implantation and the appearance of breast tumors in two of the ytterbium implanted females was comparable to that of

sham-injected females which developed mammary carcinomas.

The life spans of both the metal-implanted and control mice were not judged to be significantly different. However, the frequency of deaths due to diseases such as pneumonia, hepatitis, and nonmetal-associated neoplasms in both groups makes the life span data difficult to compare.

Discussion. The results of this experiment leave the question open as to the role of gadolinium and ytterbium in the development of sarcomas at the implantation site. However, since the appearance of sarcomas in these mice was restricted to the site of metal deposition, and since the control mice failed to develop sarcomas, these metals definitely must be implicated in the neoplastic process which occurred. The possibility that an oncogenic agent was present in the mice whose activity was promoted by an irritant, in this case, the rare earth metal, cannot be rigorously excluded. On the other hand, the subcutaneous implantation of plastics into rats has been followed by the appearance of sarcomas at the implantation site and

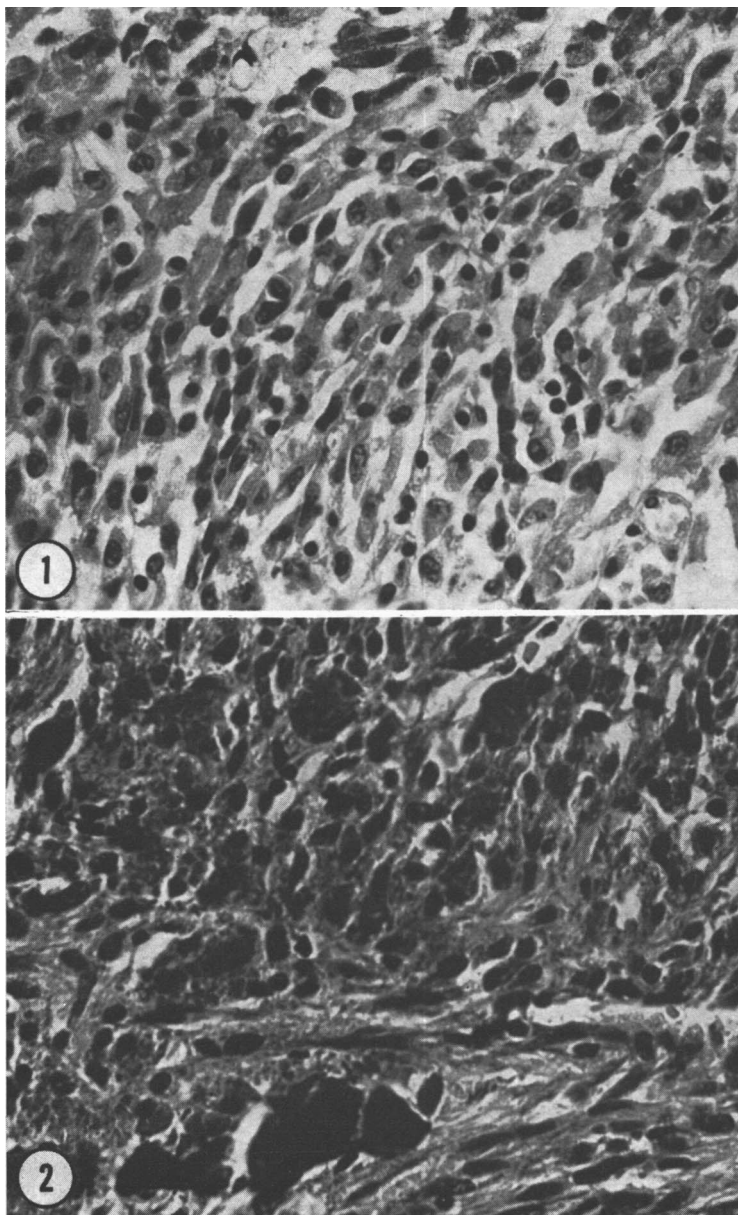


FIG. 1. Section of a cutaneous fibrosarcoma which developed following ytterbium implantation; hematoxylin and eosin, $\times 560$.

FIG. 2. Section of a cutaneous fibrosarcoma showing large deposits of residual ytterbium metal in the lower part of the photograph; hematoxylin and eosin, $\times 560$.

elsewhere (7), and Furst and Haro (8), in a recent review of metal carcinogenesis, describe various reports of induction of sarcomas in rats and mice following the subcutaneous injection of a number of metals. No

reports of sarcomas induced by injection of lanthanide metals were mentioned in the latter reference.

In an experiment similar to the authors Talbot *et al.* (2) implanted larger numbers

TABLE II. Histologic Diagnoses of Spontaneous (presumably nonrare earth associated) Neoplasms in Metal-Implanted and Control Mice.

No. of spontaneous neoplasms		Histologic diagnoses
Gadolinium-implanted mice		
Females	15	Mammary carcinoma (9); ovarian adenoma (2); bronchial adenoma (2); vulvar adenoma (1); malignant lymphoma (1).
Males	5	Bronchial adenoma (3); hemangioma (liver) (2).
Sham-implanted (controls)		
Females	13	Mammary carcinoma (7); bronchial adenoma (4); ovarian adenoma (1); salivary gland adenoma (1).
Males	4	Malignant lymphoma (2); hemangioma (liver) (1); bronchial adenoma (1).
Ytterbium-implanted mice		
Females	9	Mammary carcinoma (7); bronchial adenoma (1); malignant lymphoma (1).
Males	7	Bronchial adenoma (4); malignant lymphoma (3).
Sham-implanted (controls)		
Females	8	Mammary carcinoma (6); malignant lymphoma (1); vulvar adenoma (1).
Males	6	Bronchial adenoma (4); hemangioma (liver) (1); malignant lymphoma (1).

(714) of C57Bl mice with a number of rare earth metals and observed a very low incidence (0.4%) of sarcomas at the site of metal deposition. Of 41 malignant neoplasms which developed in the implanted mice, 3 (1 carcinoma and 2 sarcomas) were considered to be induced by the rare earth metals used (Y, Pr, and Yb). Talbot *et al.* used the criterion of visual observation of metal particles within the tumor as the basis for classifying the tumor as induced. These investigators worked with C57Bl mice, a strain reportedly more resistant to certain neoplasias such as mammary carcinoma (9). It may be that the higher incidence of implantation-associated sarcomas in our studies was due to our use of the CFW strain, which has a relatively high susceptibility to mammary carcinoma. While the authors believe the presence of metal in the tumor may be evidence implicating the metal as a tumor-inducing agent, it does not exclude the possibility that the role of the metal is that of a tumor-promoting agent, favoring the activity of a primary oncogenic agent.

To our knowledge, this report and that of Talbot *et al.* (2) are the only references which implicate rare earth metals as being associated with the development of malignant neoplasia. The oxides, when inhaled, do not appear to evoke or accelerate pulmonary or other neoplasia in the mouse or other laboratory animals (10). This may be a reflection of their extremely low solubility at physiological pH values.

If rare earth metals should be accepted as causes (or contributing factors) to neoplasia, it would support the present questionable role of metals as carcinogenic agents. In general, metals are viewed with skepticism as carcinogens, although the evidence for chromium, nickel, and the mineral asbestos is strong. On the other hand, the role of arsenic as a carcinogenic agent has had a controversial history. If the role of metallic agents is to unmask latent oncogenic agents in susceptible strains of experimental animals, it may be necessary to reevaluate metals as carcinogens.

Summary. Subcutaneous implantation of

118 CFW mice with the rare earth metals gadolinium and ytterbium was followed by the development of sarcomas at the implantation site in 12 (10.2%) of the treated mice. Pulmonary metastases occurred in 4 of the 12 cases. Comparable sarcomas did not occur in sham-injected control mice, nor were they encountered at sites other than implantation and metastasis. These results do not indicate the associative mechanism, but it would appear that these metals induce sarcomas or promote their formation by uncovering latent oncogenic factors.

Credit for initiating this research belongs to Dr. J. G. Graca, (Pharmatox Laboratories, Inc., Ames, Iowa), and to Drs. F. C. Davison and R. B. Talbot (University of Georgia, Athens, Georgia) who left Iowa State University before this research was completed. The technical assistance of Mr. C. L. Annis and Mrs. G. S. Wilson is acknowledged.

1. Haley, T. J., and Upham, H. C., *Nature* (London) **200**, 271 (1963).

2. Talbot, R. B., Davison, F. C., Green, J. W., Reece, W. O., and Van Gelder, G., *Bull. G. Acad. Sci.* **26**, 1 (1968).

3. Haley, T. J., *J. Pharm. Sci.* **54**, 663 (1965).

4. Grant, W. M., and Kern, H. L., in "Rare Earths in Biochemical and Medical Research" (G. C. Kyker, and E. B. Anderson, eds.), Oak Ridge Inst. of Nuclear Studies, AEC Report No. 12, pp. 346-351 (1956).

5. Luna, L. G., "Manual of Histologic Staining Methods of the Armed Forces Institute of Pathology," 3rd ed., p. 93 (1968).

6. Fritz, J. S., Richard, M. J., and Lane, W. J., *Anal. Chem.* **30**, 1776 (1958).

7. Hueper, W. C., *J. Nat. Canc. Inst.* **33**, 1005 (1964).

8. Furst, A., and Haro, R. T., *Progr. Exp. Tumor Res.* **12**, 102 (1969).

9. Berenblum, I., in "General Pathology" (H. Florey, ed.), 3rd ed., p. 627. Saunders, Philadelphia (1962).

10. Ball, R. A., and Van Gelder, G., *Arch. Environ. Health* **13**, 601 (1966).

Received Mar. 3, 1970. P.S.E.B.M., 1970, Vol. 135.