

Combined Surgical and Radiation Injury. VII. Trace Element Studies of the Healing Wound (36145)

ROBERT M. DONATI, ELVIO A. LEVRI, AND LAWAYNE R. STROMBERG

Department of Nuclear Medicine, Saint Louis University School of Medicine and St. Louis Veterans Hospital, St. Louis, Missouri 63106; and Divisions of Biochemistry and Experimental Surgery, Walter Reed Army Institute of Research, Washington, D. C. 20012

Iron, copper, and zinc are essential nutrients required by man and animal. These elements are encountered in the transition zone between micronutrient and macronutrient trace substances. The metabolism of these trace elements has been extensively investigated; however, it was not until recently that increased awareness of the biologic importance of a micronutrient has led to the study of these substances in a variety of clinical situations. Recent evidence suggest zinc, iron, and copper may be essential for wound healing (1-7). An acceleration of the rate of wound repair reportedly follows the administration of zinc in man and experimental animals (1-3). Iron deficiency produces a retardation of wound healing (4, 5) and supplemental colloidal iron accelerates wound repair (6). In addition, iron is important in the hydroxylation of proline, which is an essential process in collagen biosynthesis. The physiologic levels of trace metals on the healing wound and the correlation of these levels with the stages of wound repair has not been investigated.

Wound healing has been the subject of considerable study over the last 50 years. Several manipulations can alter the rate of wound repair. Ionizing radiation, in doses producing the hematologic syndrome, has been demonstrated to retard normal wound contraction (8-10). We have, therefore, measured iron, copper, and zinc concentration in the granulation tissue bed sequentially following wounding in nonirradiated rats and in rats, in which wound healing has been retarded by the exposure of X-irradiation, in an attempt to correlate the rate of wound

healing with the trace metal concentration of the granulation tissue bed.

Methods and Materials. Female Wistar rats (180-200 g) were housed individually in stainless steel cages with an automatic 12-hr day-night cycle.¹ Water and food (D&G Laboratory Biscuits, D&G Laboratories, Rockville, MD) were allowed *ad libitum*.

A group comprising $\frac{1}{2}$ of the animals was exposed to 800 R in air on a rotating table delivered by means of a 250kVp X-ray unit with 0.25 mm copper and 1 mm aluminum filtration at a dose rate of 65 R/min. Nonirradiated animals were treated in a similar manner without radiation exposure. Four days after sham or actual irradiation the rats were wounded while anesthetized with ether. The dorsal skin of the rats was shaved and a 3 cm diameter circle was drawn with ink over the midline in the high lumbar region. The circle of skin was excised down to, but not through, the subcutaneous fascia. The resulting wound was left open and untreated. The longitudinal and lateral diameters of the wounds were measured at the time of wounding and at regular intervals thereafter. The products of the diameters were calculated and all of the products for an individual animal were divided by the initial product at the time of wounding. At the end of the experiment, the average wound closure rates

¹ In conducting the research described in this report, the investigators adhered to the "Guide for Laboratory Animal Facilities and Care" as promulgated by the Committee on the Revision of the Guide for Laboratory Animal Facilities and Care of the Institute of Laboratory Animal Resources, National Academy of Sciences, National Research Council.

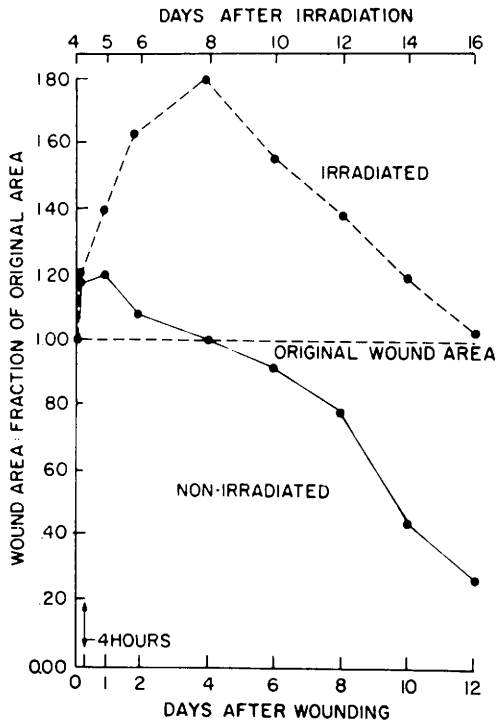


FIG. 1. Wound contraction patterns of whole body irradiated and sham-irradiated rats: Each point represents the average of 24 animals in the nonirradiated group, and a decreasing number of animals temporally in the radiated group. All averages from days 1 through 16 are significantly different for the irradiated and nonirradiated animals.

were calculated and plotted against time for each group.

Animals were sacrificed by over anesthesia 6 hr, 1, 2, 3, 4, 7, 8, and 12 days following wounding. Precautions were taken to avoid metallic contamination. Polyethylene instruments were utilized to handle granulation tissue and the samples were placed in polyethylene containers. The tissues were wet-washed with nitric and perchloric acid and the iron, copper, and zinc content of the granulation tissue bed was determined by means of atomic absorption spectrometry (Perkin-Elmer Model 303).

Results were statistically evaluated by means of Students' *t* test of significance. The 95% confidence limits were considered statistically significant.

Results and Comments. The wound contraction pattern of the irradiated and the

nonirradiated animals is presented in Fig. 1. The wounds of the irradiated animals were significantly larger ($p < .01$) at all time intervals measured. In the nonirradiated animals, the wound enlarged initially by approximately 20% and had returned to the original area by day 4 postwounding. Following postwounding day 8, the contraction process proceeded at a rapid rate and had reached 25% of the initial area by day 12. In contrast, the wounds of the irradiated animals enlarged approximately 80% and had not contracted to the original area until day 12 postwounding. The rate of wound contraction of the irradiated animals from days 12–16 postwounding paralleled the rate of the nonirradiated animals during day 8 through 12. The irradiated animals manifested retardation in wound contraction at all time intervals with a delay of approximately 4 days in the events of wound healing. These findings are in agreement with previous reports (8–10), which have demonstrated a retardation of wound repair following exposure to ionizing radiation.

The iron content of the granulation tissue in the wounds determined sequentially following wounding is presented in Fig. 2. In the nonirradiated animals, there was an initial diminution in the iron content until day 2 following wounding. The level of iron, subsequently, increased so that at day 4 following wounding, at a period of time when the wound size had again returned to the initial area, the iron content of the granulation tissue was the same level as the initial level. The iron content then continued to increase until day 8. The latter time period corresponds to a time when the wound was not healing at a rate as rapid as the subsequent rate of healing. Thereafter, between days 8 and 12, the period of most rapid wound healing, the iron content of the granulation tissue diminished.

In the irradiated animal the iron content per gram of granulation tissue was initially higher than that in the nonirradiated animal ($p < .01$). The level remained significantly higher for the period of time prior to day 4 when the rate of enlargement of the wound was greatest. However, during this period of

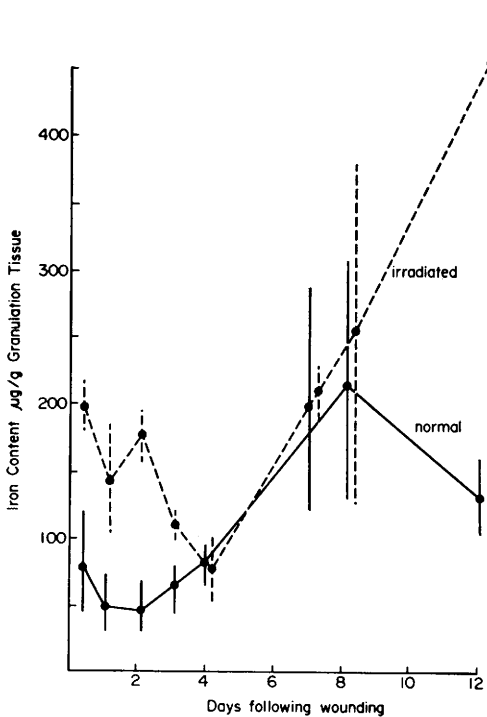


FIG. 2. Iron content of the granulation tissue of wounds from irradiated or nonirradiated rats: Each point represents the average of 12 rat wounds. The vertical lines indicate the standard deviation. Significance is discussed in the text.

time it diminished in magnitude. Following day 4 there was a progressive increase in iron content on days 8 to 12 to levels in excess ($p < .01$) of the initial levels. This period of time corresponds to the period of time when the irradiated wound is contracting at a relatively rapid rate and prior to the time that the irradiated wound has returned to the original wound area.

The initial elevation in iron levels of the granulation tissue bed of the irradiated animal may result from hemorrhage into the wound during this period of time. However, it is notable that the general shape of the curve representing granulation tissue iron content in the irradiated animal is an exaggerated parallel of the curve in the nonirradiated animal, which is delayed approximately 4 days when compared to that of the nonirradiated animal. The explanation for the phenomenon is presently unclear. The effect of radiation on the wound healing pat-

tern may be retardation of the normal sequence of events; and the changes in trace metal content observed may reflect the differing populations of cells in the granulation tissue at the time of sampling. However, it should be pointed out that iron serves an important role in enzyme systems, notably those involving peroxidases, and that ferrous ions stimulate collagen hydroxylase activity and thus the formation of collagenous hydroxyproline and hydroxylysine (11). In addition, the administration of colloidal iron has been reported to increase collagen synthesis in damaged rodent livers (7). The iron levels in the granulation tissue of the nonirradiated animals increases initially as the rate of repair and collagen formation increases. The pattern in the irradiated animals seems to reflect approximately a 4 day delay in alteration in iron levels, which correlates with the delay in wound contraction and collagen synthesis which follows irradiation. The striking parallel between the granulation tissue iron content and the wound healing pattern in the irradiated and the nonirradiated animals suggests a relationship between these two events possibly mediated by the participation of iron in enzyme activity necessary for collagen synthesis.

Iron metabolism is closely connected with copper metabolism and the formation of cross-link in elastin and probably in collagen in arterial tissue is controlled by a copper metalloenzyme (12). There is no evidence, however, that copper participates in wound healing, and some evidence that excess may be detrimental (4). Figure 3 presents the results of copper analysis of the wound granulation tissue. While the copper content of the nonirradiated wound remains remarkably constant during the 12 day period study, there appears to be a slight trend, which is statistically nonsignificant toward a decrease in copper content during the period of wound enlargement followed by a progressive increase thereafter so that by day 12 postwounding the copper content has significantly ($p < .05$) increased over the initial determination. The copper content of the irradiated wound is elevated at 6 hr following wounding when compared to the nonirradiated ani-

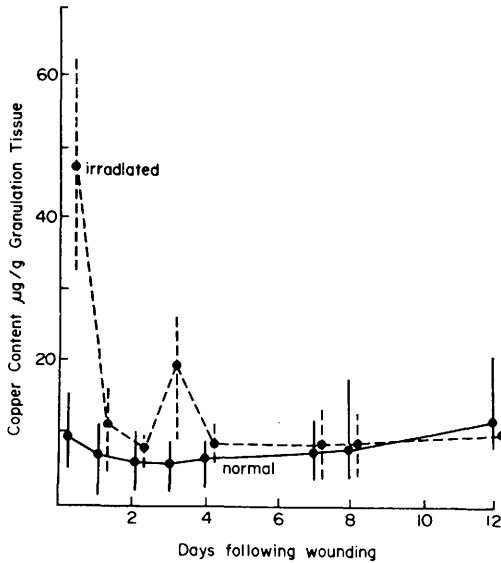


FIG. 3. Copper content of the granulation tissue of wounds from irradiated or non-irradiated rats: Each point represents the average of 12 rat wounds. The vertical lines indicate the standard deviation. Significance is discussed in the text.

mal ($p < .001$) and then appears to follow essentially the same curve as the nonirradiated animal with no significant differences except for an increase ($p < .05$) the third day postwounding which cannot be definitely correlated with any event in wound healing. The initial 6 hr increase correlates with the initial pronounced increase in wound area in the irradiated animal. However, an alternative explanation could be provided by initial hemorrhage at the site of the wound with extravasation of copper from the red blood cells. The results indicate little change in copper content with wound repair.

There is no doubt that zinc is an essential trace element closely concerned with the process of growth and repair, however, its exact role remains uncertain. The effect of exogenous zinc administration on wound healing is controversial. Several investigators suggest that the administration of zinc compounds accelerates wound repair in animals and man (1-3); others have not been able to document these findings (13-14). There is, however, general agreement that deficiency of this element results in growth retardation and a demonstrable retardation of wound

healing in animals and man, which is reversible with the restoration of zinc (15). The explanation for the intimate association of zinc with wound healing may be the fact that zinc is incorporated into many enzymes including alkaline phosphates, carbonic anhydrase, and several dehydrogenases and acts as a cofactor in many other enzyme systems. Alternatively, an explanation may be provided by the incompletely understood but vital role which zinc plays in nucleic acid and protein metabolism which may be independent of its metalloenzyme function. Thus, in the rat, zinc is necessary for hepatic DNA synthesis and for amino acid utilization (16).

The results of the analysis for zinc content in granulation tissue are presented in Fig. 4. In the nonirradiated animal there appears to be a trend toward a decrease at 24 hr, although not statistically significant, relative stability between days 1 and 4 up to the

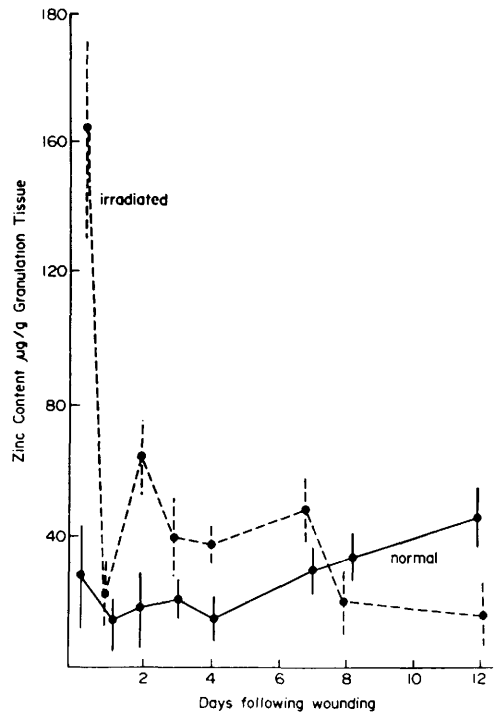


FIG. 4. Zinc content of the granulation tissue of wounds from irradiated or nonirradiated rats: Each point represents the average of 12 rat wounds. The vertical lines indicate the standard deviation. Significance is discussed in the text.

period of time when the wound reaches its original wound areas and then by a steady increase in content up to and including day 12. The wound contraction pattern has a rapid rate of contraction during the periods of time from days 4 to 12 which corresponds to the time of increasing zinc concentration.

In the irradiated wound, which demonstrates a retardation of wound healing, the zinc content is initially extremely high and falls to a steady level by day 3 where it remains through day 6. This elevation is characterized by the period of time that the wound requires to approach its original wound area. Subsequently, up to day 12, there is a further decrease in zinc content to levels below those of the nonirradiated wounds on both days 8 and 12. The initial part of the curve is a parallel of the nonirradiated curve up to day 6 postwounding, except that the zinc content of the granulation tissue remains higher in the irradiated wounds at all time intervals. From days 6 to 12, when healing is proceeding most rapidly in the nonirradiated animal, the granulation tissue zinc content increases; whereas in the irradiated animal, where the wound healing pattern has not achieved a parallel rate, the zinc content of the granulation tissue bed is rapidly diminishing. These results would suggest that the time of sampling following wounding is very important in determining the relationship of granulation bed zinc content and the rate of wound repair. Henzel *et al.* (17), in evaluating the zinc content in the granulation tissue of patients with impaired wound healing, found decreased zinc content compared with controls. Although there was no attempt to increase exogenous zinc in our animals, we noted diminished zinc content in the granulation tissue bed of irradiated rats with retarded wound healing.

The explanation for these phenomena is presently unclear. The question of whether the primary defect in wound repair is due to altered zinc metabolism or whether the changes in zinc concentration are secondary to dysfunction of enzyme or protein synthesizing systems of which zinc is an essential part cannot be answered by means of this study, but remains for future investigation.

Summary. Ionizing radiation in the midlethal range retards the wound healing pattern in rats. Iron, copper, and zinc content was sequentially determined in the granulation tissue of wounds of irradiated and nonirradiated rats for a period of 12 days following wounding. The copper levels remained constant in both groups. The granulation tissue iron content paralleled the wound healing pattern. In irradiated animals where wound healing is delayed by 4 days, the iron curve is also delayed. The granulation tissue zinc content of nonirradiated rats increased from days 4 to 12 during the period of most rapid wound contraction. The wound zinc content of the irradiated rat was decreased during this period.

1. Strain, W. H., Pories, W. J., and Hinshaw, J. R., *Surg. Forum* **11**, 291 (1960).
2. Pories, W. J., Henzel, J. H., Rob, C. G., and Strain, W. H., *Ann. Surg.* **165**, 432 (1967).
3. Cohen, C., *Brit. Med. J.* **2**, 561 (1968).
4. Chvapil, M., Hurych, J., and Ehrlichova, E., *Exp. Med. Surg.* **26**, 52 (1968).
5. Bains, J. W., Crawford, D. T., and Ketchum, A. S., *Ann. Surg.* **164**, 243 (1966).
6. Kent, G., Volini, F. I., Minick, O. T., Orfei, E., and Hueriga, J., *Amer. J. Pathol.* **45**, 129 (1964).
7. Peterkofsky, B., and Udenfriend, S., *J. Biol. Chem.* **238**, 3966 (1963).
8. Stromberg, L.W. R., Woodward, K. T., Mahin, D. T., and Donati, R. M., *Ann. Surg.* **167**, 18 (1968).
9. Stromberg, L.W. R., Woodward, K. T., Mahin, D. T., and Donati, R. M., *Experientia* **23**, 1064 (1967).
10. Stromberg, L.W. R., McLaughlin, M. M., and Donati, R. M., *Proc. Soc. Exp. Biol. Med.* **129**, 140 (1968).
11. Prockop, D. J., and Juva, K., *Proc. Nat. Acad. Sci. U.S.A.* **53**, 661 (1965).
12. Kim, C. S., and Hill, C. H., *Biochem. Biophys. Res. Commun.* **24**, 395 (1966).
13. Groundwater, W., and MacLeod, I. B., *Brit. J. Surg.* **57**, 222 (1970).
14. O'Riain, S., Copenhagen, H. J., and Calnan, J. S., *Brit. J. Plast. Surg.* **21**, 240 (1968).
15. Miller, W. J., Morton, J. D., Pitts, W. J., and Clifton, C. M., *Proc. Soc. Exp. Biol. Med.* **118**, 427 (1965).
16. Vallee, B. L., *Physiol. Rev.* **39**, 443 (1959).
17. Henzel, J. H., DeWeese, M. S., and Litchi, E. L., *Arch. Surg.* **100**, 349 (1970).

Received Sept. 15, 1971. P.S.E.B.M., 1972, Vol. 139.