

SCIENTIFIC PROCEEDINGS.

VOLUME XXIII.

DECEMBER, 1925.

No. 3.

New York Meeting

*College of Physicians and Surgeons, Columbia University,
New York City, December 16, 1925.*

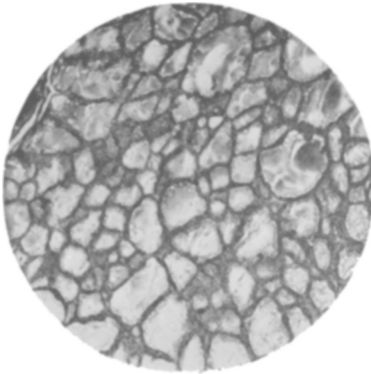
2878

Observations on effects of iodine administration in dogs following hemithyroidectomy and unipolar ligation.


W. HOWARD BARBER.

[From the Department of Experimental Surgery, University and Bellevue Hospital Medical College, New York City.]

In a previous communication before this society, it was reported that hyperplasia of the acinar cells was frequently observed in the dog following the removal of one lobe and the ligation of the superior pole of the remaining lobe. During the past year these experiments have been continued under similar experimental conditions, but, in addition to hemisection and ligation, iodine was administered either in the food or by subcutaneous injection as sodium iodide in 10 per cent solutions. Excepting in the first three animals, 10 cc. of the solution was given by subcutaneous injection daily for the post-operative period of 5 to 38 days. The experimental animals were mongrels of medium size, of probable mean weight of 7 kilograms. The data on the accompanying table is incomplete, but in so far as one can estimate from the available material, hyperplasia did not develop in this series of postoperative animals. Compared with the forego-

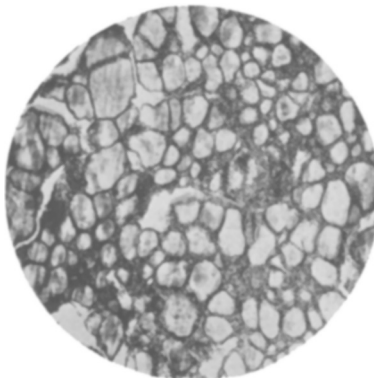


19 PRE-OP. THYROID.

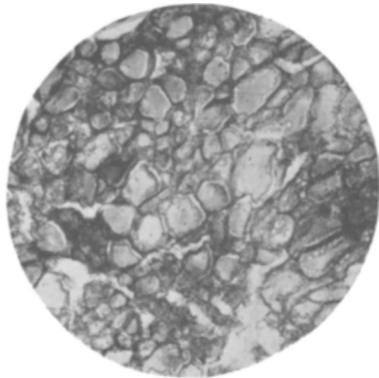


19 POST-OP. THYROID.

No. 19. Thyroid before and after lobectomy and iodine administration showing colloid-filled acini without hyperplasia 23 days after operation. Superior polar vessels were ligated at time of thyroidectomy.



60 PRE-OP. THYROID.



60 POST-OP. THYROID.

No. 60. Thyroid before and after lobectomy and iodine administration, showing colloid accumulation and similar sections 31 days after operation. Superior polar vessels were ligated at time of thyroidectomy.

ing series in which iodine had not been given, the hyperplasia is much less evident; in a few the activity of the acinar cells is less marked than before lobectomy; and in nearly all, the acini appear well filled with colloid. These observations appear to corroborate those reported by Marine (Harvey Lectures, 1924-25) and to corroborate the contention that iodine administration not only causes a diminution of hyperplasia in simple goitre, but, when given in proper dosage, prevents hyperplasia.

Thyroid from normal dog		Thyroid after hemithyroidectomy, unipolar ligation and iodine administration
Exp No.		
19 Normal or slightly hyperplastic	after 23 days	Normal
20 Slightly hyperplastic	7 "	Normal or slightly hyperplastic
22 No specimen	?	Normal
25 Normal or slightly hyperplastic	?	No specimen
32 No specimen	?	Normal
33 Slight hyperplasia	?	Normal
35 Slight hyperplasia	7 "	Normal
37 No specimen	10 "	Normal
38 Hyperplasia	?	Hyperplasia (less)
40 Normal	?	Normal
46 Hyperplasia	5 "	Hyperplasia
51 No specimen	5 "	Normal or slightly hyperplastic
52 Normal or slightly hyperplastic	38 "	Normal or slightly hyperplastic
60 Slightly hyperplastic	31 "	Normal or slightly hyperplastic

2879

Comparison of non-irradiated and irradiated cholesterol to inhibit the hemolytic action of digitonin.

ALFRED F. HESS and ELIZABETH SHERMAN.

[From the Department of Pathology, College of Physicians and Surgeons, Columbia University, New York City.]

As is well known, digitonin exerts a hemolytic action on red blood corpuscles, and cholesterol has the power to inhibit this activity. In view of the fact that our experiments have shown that the chemical properties of cholesterol are altered in various ways as the result of irradiation with ultra-violet light, it seemed worth investigating whether its property of inhibiting the action of digitonin remained unchanged after irradiation.

A comparison was made of the effect, in relation to hemolysis, of ordinary cholesterol with that of cholesterol which had been irradiated for periods of 1/2, 2 and 10 hours with the radiation of a mercury vapor lamp, set at a distance of 1 foot. For this purpose a suspension of 1 per cent ethereal solution of cholesterol and 0.1 per cent digitonin was tested on the red cells of the dog and of the sheep. Without going into detail at this time, it may