

Illinois Branch.

Northwestern University, February 28, 1928.

3889

Development of Argyrophile and Collagenous Fibers in Tissue Cultures.*

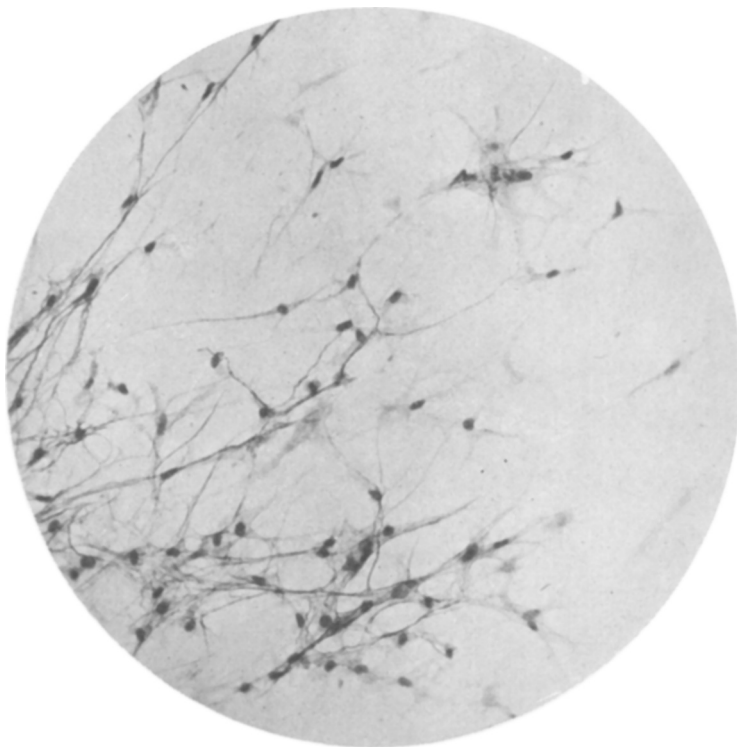
ALEXANDER MAXIMOW.

From the Department of Anatomy, University of Chicago.

In cultures of adult connective tissue of the rabbit which grow undisturbed on slides or in flasks in the usual plasma and embryonic extract medium for a period of 2 to 3 weeks, development of a fibrous intercellular substance can be observed in the living condition as well as after fixation and staining. In the first stages of this process, extremely delicate loose networks of thin, wavy, branching and anastomosing fibrillae appear around the isolated star shaped fibroblasts which advance into the nutritive medium. The fibrillae are argyrophile, *i. e.*, they are electively impregnated with silver. Although in many places they follow the outlines of the fibroblasts and their processes, and even adhere closely to their protoplasm, the fibrillae are also seen from the very beginning to extend far into the surrounding medium. As the outlines of the fibroblasts are always very distinct, the existence of an exoplasm can be excluded with certainty. The fibrillae sometimes seem to follow the course of the threads of the fibrin network. A direct transformation of the latter into argyrophile fibrillae, however, cannot be proved. (Fig. 1.)

In later stages, which can be observed in the inner areas of the zone of newly formed tissue, the argyrophile fibers become thicker and more numerous, and form dense networks. They continue to adhere to the surface of the fibroblasts, so that the cell bodies often seem to be surrounded by black, basketlike networks. The spaces between the cells are also penetrated by an increasing number of

* This work has been conducted under a grant from the Douglas Smith Foundation for Medical Research of the University of Chicago.




MICROPHOTOGRAPH 1.

Culture of connective tissue of 21 day (3 transplantations). Formation of argyrophile fibrillae around and in connection with fibroblasts. 200 x.

branching argyrophile fibers connected with the pericellular networks. If epithelial strands are present in the culture, as, for instance, in the cultures of the thymus, dense argyrophile basement membranes appear on the surface of the epithelium.

The branching and interlacing fibrillae gradually become arranged in parallel, longitudinally striated strands or bundles, which stretch in various directions and are connected everywhere by looser networks of argyrophile fibrillae. The heavier bundles are quite independent from the cell bodies; the latter may be only adjacent to their surface. In cases where the fibrin layer, in which the culture is growing becomes detached from the bottom of the flask and contracts, the strands of argyrophile fibers acquire a typical, regular, wavy appearance.

In the later stages the quantity of the fibrous substance continues to increase and the bundles become heavier. Simultaneously the fibers in the thicker bundles lose their argyrophilia and become



MICROPHOTOGRAPH 2.

Culture of connective tissue of 45 days (7 transplantations). Formation of wavy collagenous bundles from argyrophile fibrillae. 320 x.

acidophilic. After silver impregnation they are brown instead of black; with the van Gieson or Mallory stain they are intensely red or blue respectively (Fig. 2.) Everywhere in the newly formed tissue gradual transitions from black to brown (red or blue) wavy fibrillar bundles can be observed. Thus, the fibrous intercellular substance acquires all the morphological properties of true collagen. In the latest stages observed (30-50 days) large areas in the cultures were occupied by sheets of heavy, regularly arranged, wavy collagenous bundles with cells scattered between them. Such a tissue looked exactly like a small tendon or a fibrous membrane, as found in the body.

That the fibrous substance was true collagen was shown by the digestion test. In alcohol fixed material an alkaline pancreatin solution dissolved the cells and the fibrin, but left the fibrous masses unchanged.

It may be added that the same formation of fibers was also ob-

served in cultures of connective tissue, which were obtained from the buffy coat of centrifuged blood of the guinea pig.

Thus, abundant formation of true collagen can be obtained in cultures of adult mammalian connective tissue. The process follows the same paths as in the body. At first argyrophile fibrillar networks appear which in every respect are identical with the so-called reticulin or lattice fibers ("Gitterfasern"). Later, with continued increase in quantity, the fibers become arranged in parallel, wavy bundles, lose the argyrophilia and begin to stain in the fashion of mature collagen. Nothing could be observed which would substantiate the idea of the transformation of the cellular protoplasm or exoplasm into reticulin or collagen. The first fibrillae appear in the medium surrounding the cells, as the result of precipitation or, perhaps, of transformation of some colloidal sol into a gel under the influence of an unknown factor, probably of chemical nature, which originates in the cell body of the fibroblasts and diffuses into the surrounding medium. Therefore the fibrillae first arise in the immediate neighborhood, sometimes directly on the surface of the protoplasm. They, however, extend at once far into the medium, away from the cells. It is probable, that, as Heringa and Lohr¹ suggested, the particles of the colloids in question are rod shaped. This causes the gel to assume a fibrillar structure. The fibrin threads of the plasma clot seem to serve as pathways for the precipitating material. Whether the fibrin itself is transformed into reticulin and later into collagen (Baitsell²) is doubtful.

¹ Heringa, G., and Lohr, H., *Kon. Akad. v. Wetensch. te Amsterdam*, 1926, xxvi, 1081.

² Baitsell, G., *J. Exp. Med.*, 1915, xxi, 455.

3890

Symptoms Resembling Epilepsy Following Experimental Lesions in Brain of the Dog.

LAWRENCE O. MORGAN AND CLARENCE A. JOHNSON.

(Introduced by V. E. Emmel.)

*From the Department of Anatomy and Laboratory of Physiological Chemistry,
University of Illinois College of Medicine.*

This study is based on 16 dogs in which a lesion was successfully placed in the mammillo-infundibular region of the diencephalon.