

but definite fluid levels could be seen in the X-ray film. In the 2 dogs in which strangulation obstructions were established gaseous distension of the proximal loops was noted on the X-ray film, but the strangulated segments failed to exhibit dilatation. A report of further X-ray studies on strangulation obstruction will be made subsequently.

In the instances in which barium was given through a gastrostomy tube an interval of 20 hours was usually necessary before the barium reached the site of intestinal block. The employment of contrast media to determine the presence of bowel occlusion is to be condemned, but flat plates of the abdomen constitute a measure of real value in detecting intestinal stasis. The stethoscope will serve to differentiate whether the obstruction is mechanical or inhibitive. The former exhibits loud intestinal noises; in the latter the abdomen is silent.

## 4913

**Motor Activity of the Distal Bowel in Intestinal Obstruction:  
Comparison with the Obstructed and Normal.**

HERBERT A. CARLSON AND OWEN H. WANGENSTEEN.

*From the Department of Surgery, University of Minnesota.*

The bowel distal to the point of obstruction is normal anatomically, whereas the proximal bowel exhibits anatomical changes. Alvarez<sup>1</sup> states that most of the motor activities of the stomach and bowel are brought about and regulated largely by the internal pressure due to the presence of food or gas, on which basis an eventual condition of inactivity in the bowel distal to a complete obstruction would appear to be understandable. But the distal bowel has been found to evacuate enemas and transport barium in approximately normal time. In this study an attempt has been made to study the motor activity of the distal segment of the bowel in the presence of simple obstruction. There were 22 dogs obstructed, the point of severance being usually 3 to 5 feet above the ileo-caecal valve. The proximal end was turned in and the distal end anchored to the skin in 8 dogs. In 14 others both ends were inverted.

Small rubber balloons were inserted into the bowel and the contractions of the bowel recorded upon a smoked drum by means of a

---

<sup>1</sup> Alvarez, W. C., "The Mechanics of the Digestive Tract." Paul B. Hoeber, New York. 1928. 24.

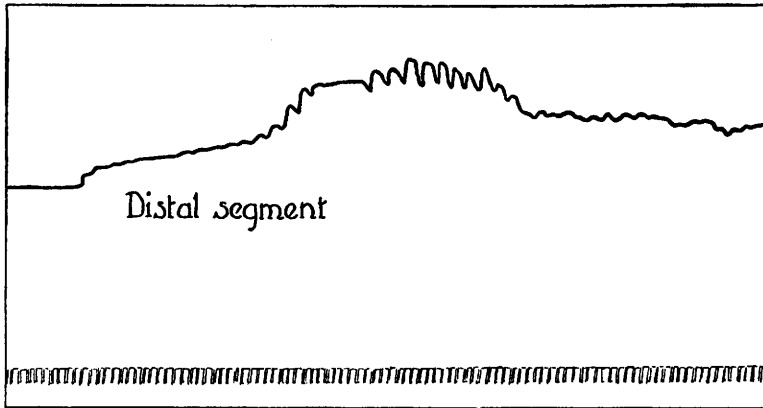


FIG. 1. Dog obstructed 30 hours. Tracing of distal segment.

water manometer. From the distal segment tracings could be obtained through the enterostomy without the employment of anesthesia.

Tracings in the normal bowel show rhythmic contractions occurring about 10 to 15 times per minute. The height of the contraction varies to such an extent in different animals and at different times in the same animals that no numerical average can be adopted for quantitative comparisons. However, tracings of the distal loop

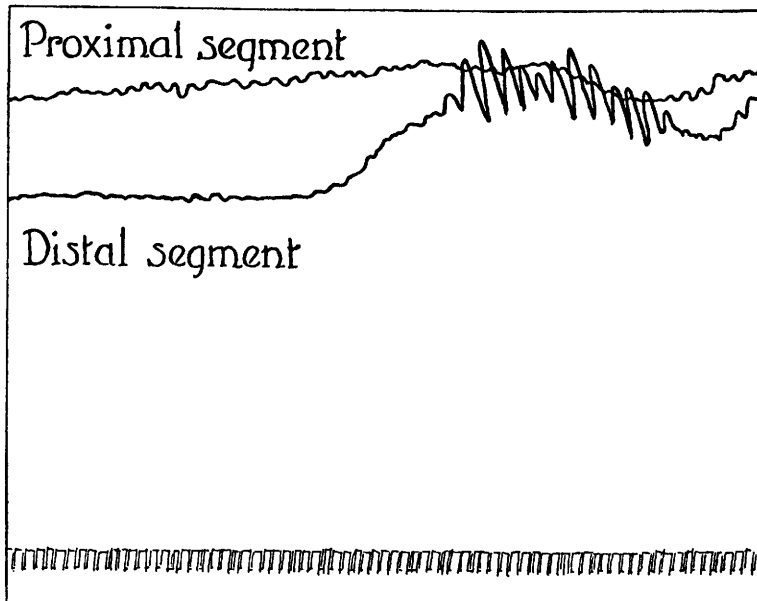


FIG. 2. Dog obstructed 5 hours.

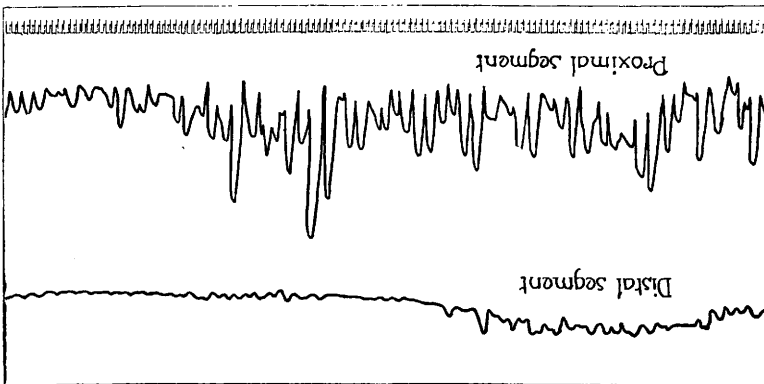


Fig. 3. Dog obstructed 7 days.

resemble closely tracings of the normal bowel studied under similar conditions.

In a comparison of the activity of the proximal and distal loops recorded simultaneously on the same tracing in 13 experiments the greater activity occurred in the proximal loop 5 times, in the distal loop 7 times and in one case (Fig. 2) the greater activity occurred first in the proximal and later in the distal segment. In this small series of observations, therefore, the greater activity was found more commonly in the unobstructed bowel.

On the other hand, comparison of the maximum contractions of the various bowel loops indicate that the obstructed loop shows the

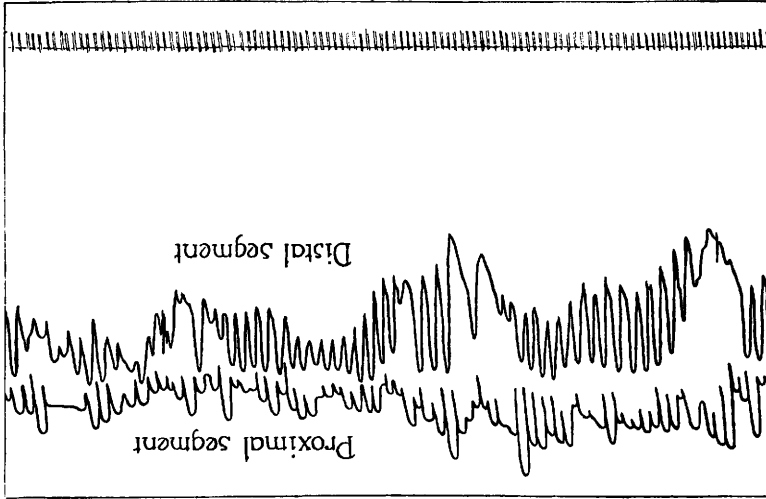


Fig. 4. Dog obstructed 6 days. Spinal anesthesia.

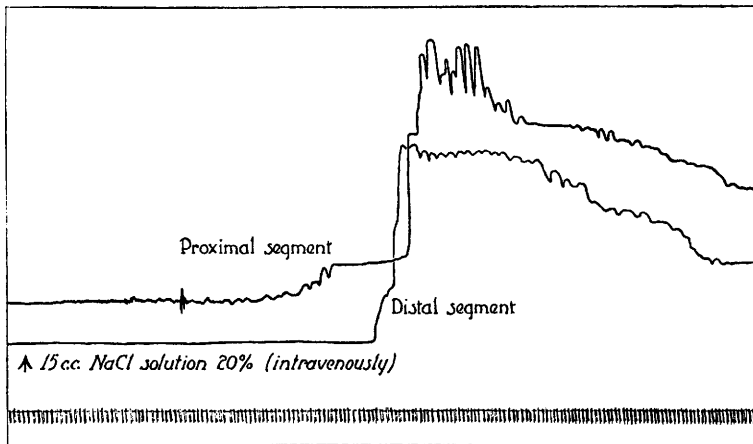


FIG. 5. Effect of hypertonic salt solution.

greatest maximum contractions; the normal bowel is intermediate and the maximal contraction of the loop below the obstruction does not attain that of the other two.

The differences in the maximum contractions, if they are significant at all, are undoubtedly dependent upon the intra-intestinal pressure, for the sustained intra-intestinal pressure in the obstructed bowel is about twice that of the normal and during activity may arise to 10-15 times the normal pressure. (Owings and associates.<sup>3</sup>)

Figures 1-4 illustrate variations in the relative activity of the bowel segments in different tracings. The great activity of the bowel segment obstructed for 7 days (Fig. 3) is unusual and is in disagreement with the findings of Owings and his associates, who observed a decrease of pressure and activity after the fifth day. The greater incidence of peritonitis in the pressure experiments may




FIG. 6. Effect of pilocarpin.

<sup>3</sup> Owings, J. C., McIntosh, C. A., Stone, H. B., and Weinberg, J. A., *Arch. Surg.*, 1928, xvii, 507.

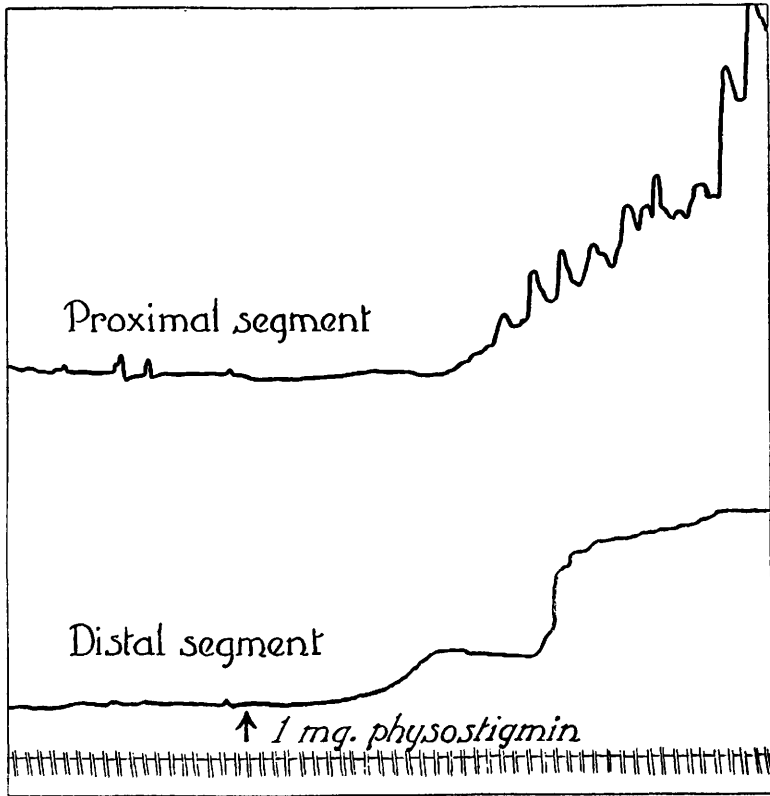


FIG. 7. Effect of physostigmin.

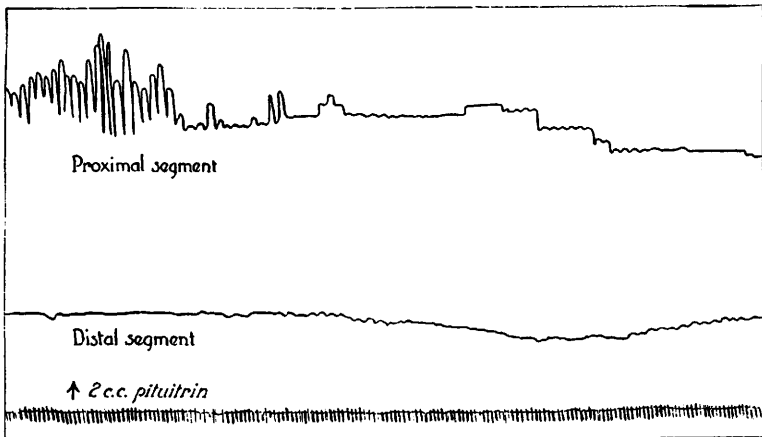


FIG. 8. Effect of pituitrin.

play a rôle although Hotz<sup>4</sup> believed that the decreased function of the bowel in peritonitis was due to gaseous distension.

The action of pituitrin (Fig. 8) occasioned not a little surprise. Doses of 0.5 cc. to 2 cc. of surgical pituitrin intra-muscularly caused no response at all or a depression of the intestinal movements. A dose of 1 cc. intravenously resulted in a reduction of the activity and decrease of the tone. The greater effect appeared to be on the segment of bowel which at the time showed the greater activity regardless of whether this was the obstructed or the unobstructed segment. In some cases the period of inactivity was followed by one of activity but in no case did the secondary activity exceed that prior to the administration of the drug. The same results were obtained in the study of the effect of pituitrin on the normal bowel. Our findings agree with those of McIntosh and Owings<sup>5</sup> who also point out that the literature relative to the effect of pituitrin on the bowel is in disagreement. Further work is needed to clarify the action of this drug on the intestine of man and laboratory animals under normal and pathological conditions.

In conclusion it may be said that the segment of bowel distal to a complete obstruction has a capacity for normal physiological activity and responds to chemical stimuli in a normal manner. This segment of the bowel is normal physiologically as well as anatomically.

#### 4914

### Electrocardiographic Diagnosis of the Artery Occluded in Cardiac Infarction.

WERNER J. ROSE AND FRANK MEYERS. (Introduced by B. D. Bowen.)

*From the Buffalo General Hospital and the School of Medicine, University of Buffalo.*

Changes in the electrocardiogram due to cardiac infarction have been noted by many observers, and reports of clinical cases give us our most valuable information because the coronary system in the common laboratory animals does not parallel the human coronary circulation. Thus it is not possible to study the effect of infarction in various parts of the animal heart by laboratory methods and apply these findings to human cases.

---

<sup>4</sup> Hotz, G., *Mitteil. a. d. Grenzgeb. d. Med. u. Chir.*, 1909, xx, 257.

<sup>5</sup> McIntosh, C. A., and Owings, J. C., *Arch. Surg.*, 1928, xvii, 996.