

obtained is striking in several respects and simulates those described by Graham in human cases of arteriolar-sclerosis. First the roughly beaded appearance of the vessels and, secondly the incomplete and patchy injection of the vascular bed.

5310

Studies in Renal Denervation. I. Roentgenographic Demonstration of Vascular Alteration.*

G. MILLES, E. F. MÜLLER AND W. F. PETERSEN.

From the Department of Pathology and Bacteriology, University of Illinois College of Medicine, Chicago, and the Medical Department, Eppendorfer Krankenhaus, Hamburg.

The physiological and anatomical changes induced by denervation of the kidney have been carefully studied by Seres,¹ Ellinger and Hirth,² Bieter,³ Bradford,⁴ Gironcoli,⁵ and others. Gironcoli concludes that the results are chiefly: 1. Increase in the size of the kidney; 2. Generalized thickening of the capsule which he considers nontraumatic; 3. A dilatation of the arterioles and capillaries as seen in the microscopic section. Seres concludes that the changes are: 1. Increase in volume of the urine; 2. Decrease in the specific gravity due to a decrease in the solids per unit of volume, but 3. Little change in the total solids. 4. Earlier and more effective response to the diuretic effect of sodium chloride and glucose.

As a preliminary to a study of the effect of various agents upon the normal and denervated kidneys, we are reporting here the changes in the vascular bed as demonstrated by roentgenogram using the method described in a previous paper.

The denervation was accomplished as follows: Dogs were kept under Nembutal (Abbott) anesthesia, the kidney was exposed and delivered through an incision 2 cm. below and parallel to the costal margin and extending from a point about 3 cm. from the spinous

* The present investigation was aided by a grant from the Josiah Macey, Jr., Foundation.

¹ Seres, M., *Rev. Med. de Barcel.*, 1924, **1**, 220. Abstracted *Z. f. Urol. Chir.*, 1925, **17**, 54.

² Ellinger, P. H., and Hirth, A., *Arch. f. Exp. Path. u. Pharm.*, 1925, **106**, 135.

³ Bieter, R. N., *Proc. Soc. Exp. Biol. and Med.*, 1929, **26**, 792.

⁴ Bradford, J. R., *J. Phys.*, 1889, **10**, 358.

⁵ de Gironcoli, F., *Z. f. Urol. Chir.*, 1929, **27**, 26.

processes anteriorly for a distance of 5 to 8 cm. The peritoneal sheath over the kidney was divided and the pedicle fat and connective tissue stripped away. The macroscopic nerves were divided and the vessel sheaths removed. The renal artery was deprived of its adventitia as far as this was possible by scraping between the blades of the hemostat.

After a period of 2 or more weeks the animals were utilized for injection of the renal vessels.

The injection, as was pointed out previously, filled the arterial

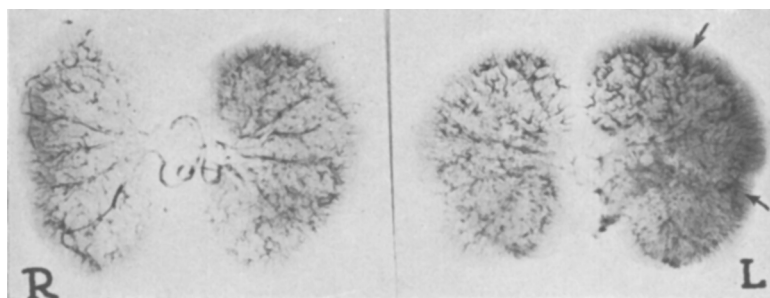


FIG. 1.

Injected kidneys, left kidney denervated two weeks prior to injection. Note the wider vascular bed of the left kidney, especially the increased number of arteriae recti.

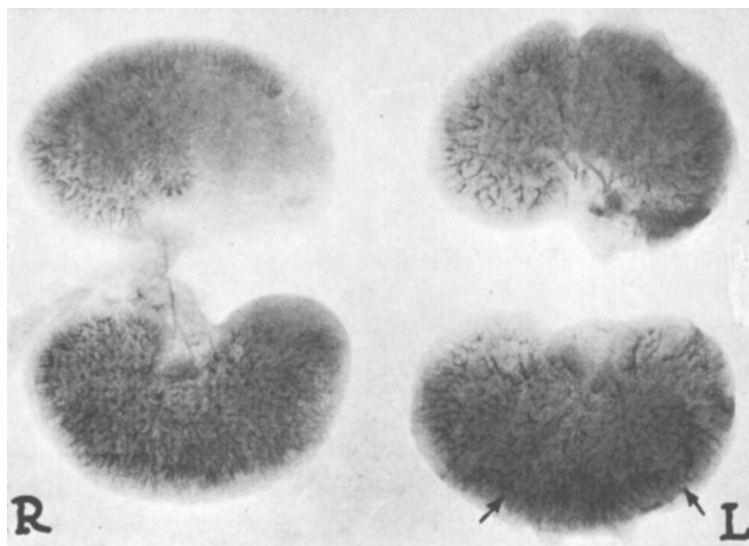


FIG. 2.

Injected kidneys, left kidney denervated three weeks prior to injection. Note the wider vascular bed of the left kidney, especially the dilatation of the arteriae recti, and lack of injection of one-half of one pole of the right kidney.

tree including the interlobular arteries with bismuth oxychloride to a sufficient degree to render them opaque to x-ray. The roentgenogram obtained was an accurate delineation of their outlines.

In interpreting changes the normal and denervated kidneys were compared as to the regularity in the outline of their vessels, the extent to which the interlobular vessels penetrated the cortex, and the relative number of vessels seen.

In general this series resulted in 2 types of pictures. The first, constituting the majority, showed the denervated kidney to be larger, the vessels to be more dilated, and the number and projection of the interlobular arteries to the outer margin of the cortex to be greater in the normal kidney. (Figs. 1, 2, and 3.) The sec-

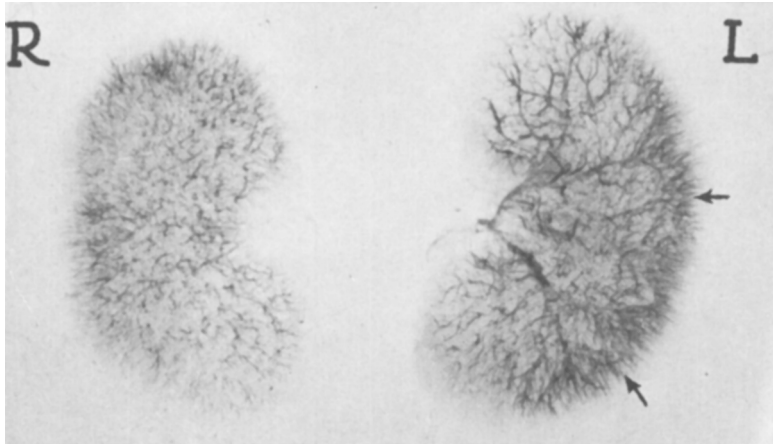


FIG. 3.

Injected kidneys, left kidney denervated forty-eight hours prior to injection. Note general vascular dilatation and particularly the larger arteriae recti and their more marked projection to the margin of the cortex.

ond group into which but few pictures fell was characterized by decrease in size and a marked decrease in the number of injected vessels in the denervated organ. The interlobular vessels extended only a short distance into the cortex in these specimens. In these, the denervated kidney was generally smaller than the normal. Correlation of the pictures with the histological findings showed in the first group dilatation of the interlobular vessels and glomerular tufts with the vessels and kidneys parenchyma well preserved. In the second group, vascular changes of a degenerative type such as endothelial swelling and rarely interstitial hemorrhages were found.

Conclusions. We have demonstrated in a pictorial manner the general types of vascular change resulting from denervation; (1) a

general dilatation of the vascular bed; (2) some degenerative changes affecting chiefly the blood vessel intima.

5311

Stability of Esterase and Ereptase in Ground Liver and Kidney Preserved in Glycerol.

O. R. CAILLET. (Introduced by J. P. Simonds.)

From the Department of Pathology, Northwestern University Medical School.

It was shown¹ that ground dog's liver preserved in pure glycerol had retained its peptone and ester-splitting powers unimpaired for a period of 34 months. In some instances it was found that the extract showed an even greater esterolytic power after standing in glycerol for nearly 3 years than after extraction for a period of 21 days.

The ground organs of these experimental animals have now been

TABLE I.

Animal	Organ	Esterolytic Activity After 21 days in Glycerol Shown in cc. 0.1 NaOH	Esterolytic Activity After 13 years in Glycerol Shown in cc. 0.1 NaOH	% Gain or Loss
Ph. 16d	Liver	3.27	3.53	+7.9
Ph. 16c	"	4.15	4.20	+1.2
Ph. 17c	"	3.70	3.55	-4
Ph. 16d	Kidney	2.25	1.36	-39.5
Ph. 16c	"	3.75	1.95	-48.0
Ph. 17c	"	2.65	1.38	-48.0
Ave.	Liver	3.71	3.76	+1.2
"	Kidney	2.88	1.56	-46.0

TABLE II.

Animal	Organ	Peptolytic Activity After 21 days in Glycerol Shown in cc. 0.1 NaOH	Peptolytic Activity After 13 years in Glycerol Shown in cc. 0.1 NaOH	% Gain or Loss
Ph. 16c	Liver	1.25	0.96	-23.2
Ph. 16c	"	1.45	1.05	-27.5
Ph. 17c	"	2.35	1.75	-25.5
Ph. 16d	Kidney	4.75	2.15	-54.5
Ph. 16c	"	4.20	2.28	-45.5
Ph. 17c	"	5.50	1.85	-70.0
Ave.	Liver	1.68	1.25	-25.5
"	Kidney	4.82	2.09	-57.0

¹ Simonds, J. P., *J. Exp. Med.*, 1918, **28**, 663; *Am. J. Physiol.*, 1919, **48**, 141.