

are the nucleus filiformis, and the nuclei hypothalamicus paraventricularis ventralis, dorsalis, and posterior. The nuclei hypothalamicus anterior and parvocellularis lie in the anterior region of the infundibulum and just behind these nuclei are the nuclei hypothalamicus dorsalis, dorsomedialis, ventromedialis, and nucleus perifornicalis. In the posterior portion of the infundibulum, anterior to the mammillary region are the posterior hypothalamic nucleus and the nucleus hypothalamicus ventro-lateralis. Lateral to all of these nuclei and extending nearly the whole length of the infundibulum is the lateral hypothalamic nucleus.

The principal nucleus of the mammillary region is the medial mammillary nucleus. Surrounding this nucleus are the premammillary, inframammillary, supramammillary, and lateral mammillary nuclei. Just lateral to this group is a well defined nucleus, the nucleus intercalatus.

In the subthalamus were found the entopeduncular nucleus, zona incerta, nucleus subthalamicus, Fields H<sub>1</sub> and H<sub>2</sub> of Forel, and the substantia nigra.

Both the subthalamic and the hypothalamic regions of *Macacus rhesus* resemble very closely these areas of Carnivora, rat, and other lower mammals.

## 6915

### Ovarian Hormone and Traumatic Stimulation of Monkey's Cervix to a Condition Resembling Early Cancer.

MILTON D. OVERHOLSER AND EDGAR ALLEN.\*

*From the Department of Anatomy, University of Missouri.*

The ovarian follicular hormone has been shown by Allen<sup>1, 2</sup> to be a powerful stimulator of epithelial growth in the female genital tract and breast. Large amounts of this hormone have been reported in the blood of cancer patients, both male and female.<sup>3</sup> Also

\* This work has been assisted by a grant to Dr. Edgar Allen from the Committee for Research in Problems of Sex of the National Research Council.

<sup>1</sup> Allen, Edgar, Contributions to Embryology, No. 98, 1927. Carnegie Inst. Wash. Pub. No. 330, 1.

<sup>2</sup> Allen, Edgar, Sex and Internal Secretions, 1932, The Williams and Wilkins Co., Baltimore.

<sup>3</sup> Dingemans, E., Freud, J., de Jongh, S. E., and Laqueur, Ernest, *Arch. f. Gynäk.*, 1930, **141**, 225.

cancer tissue from men has been found to have a high content of theelin.<sup>4</sup> Lacassagne<sup>5</sup> gave theelin injections to 3 male mice from a strain in which 72% of the females developed spontaneous mammary cancer. The males of this strain normally never developed mammary cancer but the theelin injections produced mammary cancer in 5 to 6 months in each of the 3 males. Removal of the ovaries in mammary cancer strains of mice and rats markedly decreases or entirely prevents the development of spontaneous mammary cancer.<sup>6, 7, 8</sup> Hofbauer<sup>9</sup> reported that anterior hypophysis transplants and extracts in guinea pigs produced a precancerous condition in the cervix. His anterior pituitary treatment should have increased the production of the follicular hormone, although he considers that the pituitary hormone caused a direct stimulation of the cervical epithelium. These facts led us to attempt to produce cancer by injections of genital growth hormones combined with chronic trauma.<sup>10</sup>

Nine female *Macacus rhesus* monkeys were used. All except one were ovariectomized several months to 20 days before the beginning of the experiment. The cervixes were traumatized by scissor cuts through a vaginal speculum. This procedure was repeated at 7 to 10 day intervals throughout the experiment. In addition to the cuts a small metal clip was clamped on the cervix in some of the animals. Subcutaneous injections of hormone were made twice daily, morning and evening as a rule. The daily dose of ovarian follicular hormone, given as theelin or amniotin, ranged from 50 to 100 rat units. The theelin† preparation used contained 50 rat units per cc. Two preparations of amniotin‡ containing 200 and 50 rat units per cc. respectively were used.

Six ovariectomized animals (monkeys 3, 4, 6, 7, 9) received cervical trauma and injections of the ovarian follicular hormone ranging in total dosage from 1,535 to 5,490 rat units, over time periods ranging from 16 to 90 days. Three of these animals (monkeys 6,

<sup>4</sup> Loewe, S., Raudenbusch, W., and Voss, H. E., *Biochem. Z.*, 1932, **249**, 443.

<sup>5</sup> Lacassagne, M. A., *Compt. rend. Acad. d. sc.*, 1932, **195**, 630.

<sup>6</sup> Lathrop, A. E. C., and Loeb, Leo, *J. Cancer Res.*, 1916, **1**, 1.

<sup>7</sup> Cori, Carl F., *J. Exp. Med.*, 1927, **45**, 983.

<sup>8</sup> Murray, William S., *J. Cancer Res.*, 1928, **12**, 18.

<sup>9</sup> Hofbauer, J., *Zentralbl. f. Gynäk.*, 1930, **54**, 2393.

<sup>10</sup> Overholser, Milton D., and Allen, Edgar, *Anat. Rec.*, 1933, **55**, No. 4 Suppl., 32.

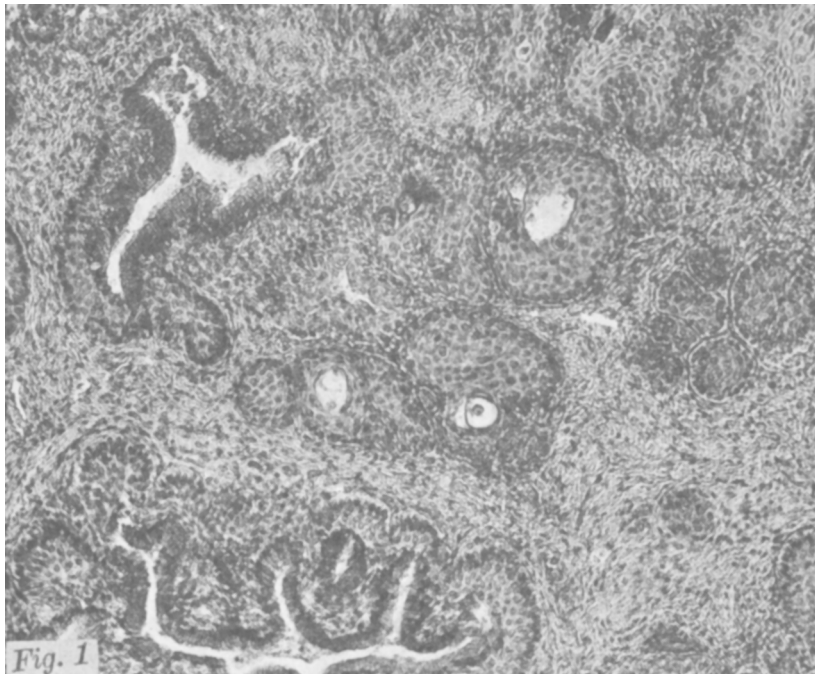† Furnished by Parke, Davis & Co. for experimental purposes.

‡ Furnished by E. R. Squibb & Sons for experimental purposes.

7, 9) also received injections of corpus luteum hormone<sup>11</sup> during the latter part of the theelin injections. One ovariectomized animal (monkey 11) received hormone injections only; 2,802.5 rat units of follicular hormone and 10.7 cc. of corpus luteum hormone in 51 days. This animal was killed 33 days after the cessation of all injections. One ovariectomized animal (monkey 10) received cervical trauma only for 86 days. One animal with ovaries intact (monkey 8) received cervical trauma only for 119 days.

We have described<sup>10</sup> the changes that occurred in the cervixes of these monkeys but realizing that we might be over-enthusiastic, we submitted our slides to Dr. James Ewing of Cornell University whose ability as a diagnostician is so well established. His pathological report follows:

*Monkey 11.* (Fig. 1). "Much papillary gland overgrowth, much epidermization, much infection, many areas of distinctly atypical

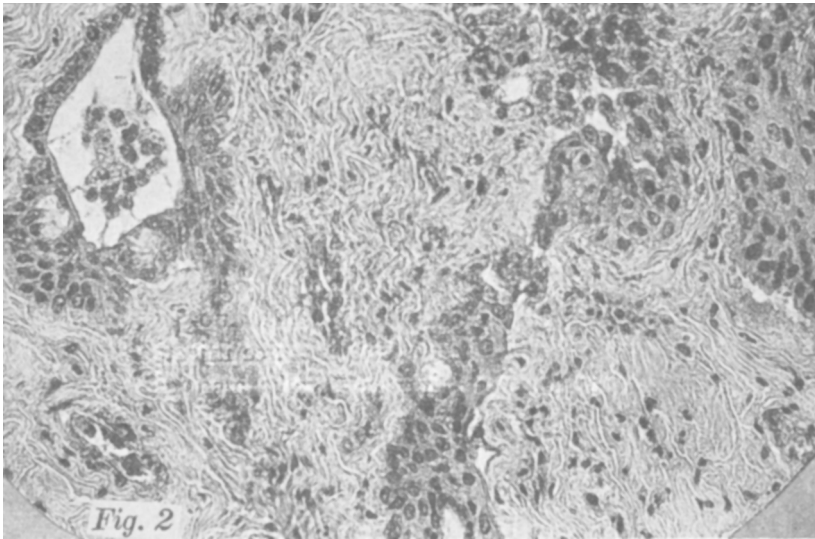


Monkey 11. Section of cervix from ovariectomized animal that received only hormone injections. No cervical trauma given. Shows a close approximation to established cancer, especially the very atypical cells.

<sup>11</sup> Prepared according to a method described by Turner, C. W., and Frank, A. H., *Mo. Agr. Exp. Sta. Res. Bul.*, 1932, **174**.

epidermoid cells. This is a close approximation to established cancer, especially the very atypical cells. I should have to pass the lesion as early but established cancer."

*Monkey 9.* (Fig. 2). "Shows early but essential features of infiltrating epidermoid carcinoma but in an ulcerating area. There is much infection which is probably an important factor." Another section from this same monkey "shows gland overgrowth, down-growth, much epidermization, somewhat atypical, much infection. This is a pronounced precancerous lesion and trauma must be given an important place."



*Monkey 9.* Section of cervix from ovariectomized animal that received cervical trauma and hormone injections. Shows early but essential features of infiltrating epidermoid carcinoma in an ulcerating area.

*Monkey 10.* Ovariectomized animal receiving trauma only: "Slight atypical downgrowth, slight infection."

*Monkey 8.* Normal animal receiving trauma only. Our own examination revealed a few areas of epidermization of the cervical glands.

A report on two semi-ovariectomized monkeys is included. They received cervical trauma and injections of follutein‡ (anterior pituitary like extract prepared from pregnancy urine). Dr. Ewing's report is as follows: *Monkey 5.* "Marked leukoplakia." *Monkey 6-1.* "Marked interstitial endocervicitis, slight precancerous changes."

Experiments are under way which attempt to further evaluate responsibility for the effects produced between hormone and traumatic stimulation.

## 6916

**Pathogenicity of *Serratia Marcescens* (*Bacillus Prodigiosus*).**

PAUL D. ROSAHN AND C. K. HU. (Introduced by L. Pearce.)

*From the Laboratories of the Rockefeller Institute for Medical Research.*

In connection with an investigation to determine the etiological agent responsible for a pandemic disease of rabbits<sup>1</sup>, filtration experiments were conducted, and all filter candles were tested in the usual manner with a strain of *Serratia marcescens* (*Bacillus prodigiosus*) obtained from Institute stocks. As the work progressed, a fortuitous observation led to an investigation of the pathogenicity of this organism. The growth from a 24 hour agar slant was suspended in 10 cc. of Locke's solution, and rabbits and mice were injected with this material. Rabbits receiving 0.3 cc. intracerebrally, or 1.0 cc. intraperitoneally, intravenously, or intratesticularly, all died within 24 hours, and all mice injected with 0.6 cc. intraperitoneally or 0.05 cc. intracerebrally also died within 24 hours. A benign course attended the use of smaller amounts of the organism.

The gross findings at autopsy were striking. Hemorrhagic peritonitis with effusion, punctate hemorrhages in the adrenals, hemorrhagic lymph nodes, and small areas of focal necrosis in the liver were constant findings. An occasional animal had consolidated patches in the lungs. The spleen was usually large and swollen. *Bacillus prodigiosus* was recovered in pure culture from the brain, liver, spleen, lymph nodes, kidneys, lung, and blood.

A second strain of the organism was obtained from another laboratory. Morphologically and culturally it was identical with our own strain. When injected into animals in the large doses previously mentioned, it too caused death in less than 24 hours, and the same pathological picture was present.

Bertarelli<sup>2</sup> reported the death of rats, guinea pigs, and mice fol-

---

<sup>1</sup> Pearce, L., Rosahn, P. D., and Hu, C. K., *Proc. Soc. Exp. Biol. and Med.*, 1933, **30**, 894.

<sup>2</sup> Bertarelli, E., *Centr. Bakt., 1. Abt., Orig.*, 1903, **34**, 193, 312.