

the index inoculum-slides, there was no increase in number, no loosening of the "globi" and no change in morphology. Furthermore, the host reaction as noted in the hematoxylin-eosin stained sections was that of a sub-acute and chronic inflammation such as occurs about an inert foreign body. The tissue reaction was characterized by lymphoid, plasma and fibroblastic cells. Neutrophils were conspicuous by their absence. Endothelial cells were present in and around the tissue particles of the inoculum. However, there was no evidence that these cells had phagocytized the *B. leprae* or that the latter had invaded them.

These results indicate to us that the multiplication of *B. leprae* does not occur *in vivo* in chick embryos within 7 to 11 days. Experiments are in progress in which successive transplants from one chick embryo to another are made. We hope to determine in this way if a longer period of incubation will result in *B. leprae* multiplication, host-cell invasion and intracellular colonization. In conclusion, we feel that living chick embryo may be satisfactory for the study of the *in vivo* behavior of *B. leprae*.

7259 C

Morphological Resemblance of the Rod Shaped Pigment of the Chick Retina to *B. Leprae*.

R. A. HOLT. (Introduced by C. W. Duval.)

From the Department of Pathology and Bacteriology, School of Medicine, Tulane University, New Orleans.

During recent attempts to cultivate *B. leprae* in embryonic chick tissues,¹ an interesting observation was made on the close morphological resemblance of this microorganism in freshly excised human leprous tissue to the rod shaped pigment of the chick retina. This observation is considered worthy of note because of the possibility of confusing these bacilli and pigment rods when employing embryonic tissue as a culture medium. Furthermore, as Rivers² points out, the presence of the pigment rods may lead to confusion when smears are made to determine the sterility of the cultures. For this reason, he suggests removing the eyes of the embryo before making

¹ Holt, R. A., PROC. SOC. EXP. BIOL. AND MED., 1934, **31**, 567, 643.

² Rivers, T. M., *J. Exp. Med.*, 1931, **54**, 453.

use of the tissue as a medium. We, however, prefer to include as much of the highly specialized tissues as possible and, therefore, make use of the entire embryo.

The rod-shaped pigments are found within the inner surface of the hexagonal epithelial cells of the retina, this layer being considered the outer layer of the optic cup. They occur normally in tightly packed masses and usually with regularity. However, their arrangement can be readily disturbed by mechanical means; that is, the packets are easily broken by ordinary manipulation and their component rods are freely scattered when embryos are either minced or sectioned. When this dispersion occurs, these pigment rods and packets can be mistaken morphologically for those of *B. lepræ* and the "globi" found in human leprous tissue. The individual pigment rods are 1-5 μ in length, dark brown in color and resistant to the penetration of dyes. The distribution of the pigment within the rods is usually homogeneous, but sometimes it is irregular and simulates the chromatin "beading" so characteristic of acid-fast bacilli.

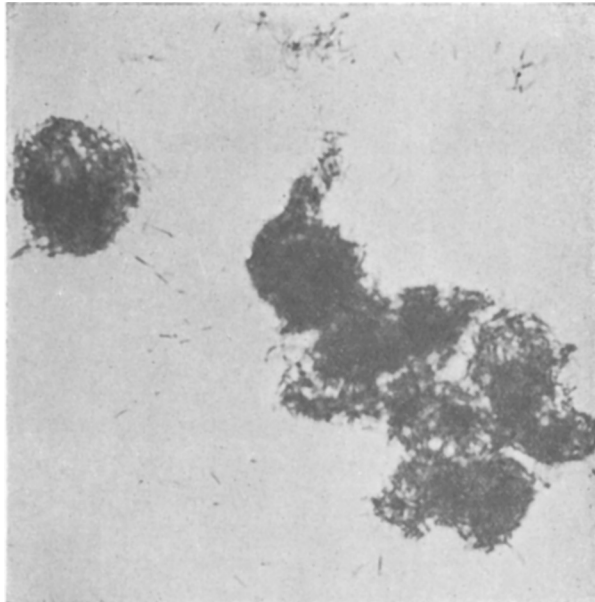


FIG. 1.

Smear preparation of chick embryonic tissue showing "globus" appearance of rod shaped pigment within the epithelial cells of the retina. A few individual rods are scattered while others are in small packets. Ziehl-Neelsen stain. $\times 1000$.

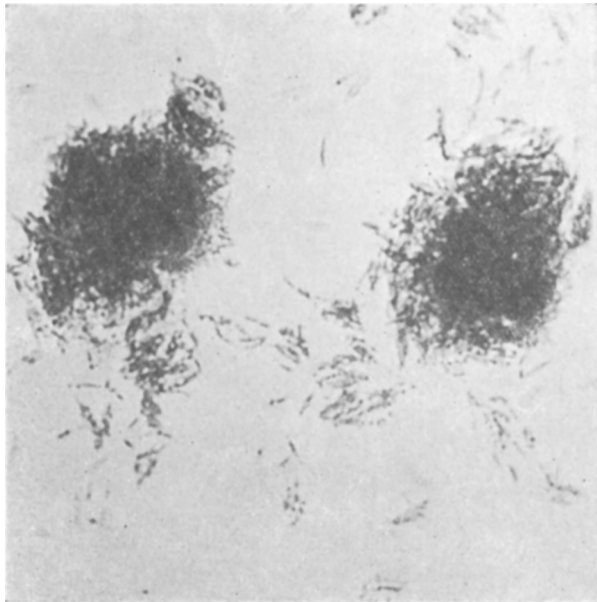


FIG. 2.

Smear preparation from human leprous nodule showing typical "globi". Some of the leprosy bacilli are seen free from the tightly packed masses while others occur in small clusters. Ziehl-Neelsen stain. $\times 1000$.

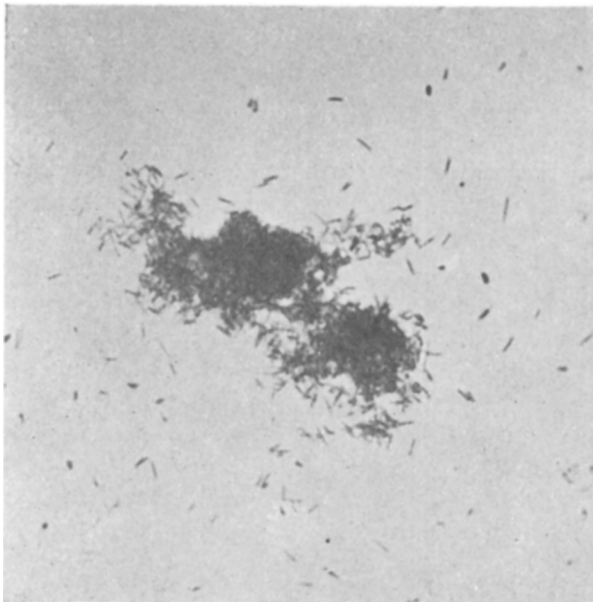


FIG. 3.

Mechanical dispersion of the rod-shaped pigment after rupture of the chick retinal epithelial cells. Ziehl-Neelsen stain. $\times 1000$.

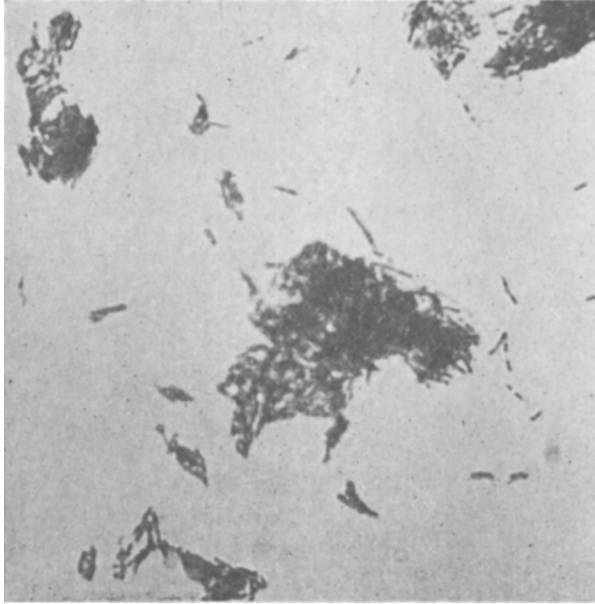


FIG. 4.
Mechanical dispersion of *B. leprae* after rupture of the characteristic leprous "globi". Ziehl-Neelsen stain. $\times 1000$.

Differentiation of these pigments and bacilli can be made by tinctorial means. The best staining method for this purpose is that of Ziehl-Neelsen, since *B. leprae* is acid-fast while the pigment rods remain brown. The Gram and hemotoxylin-eosin stains can be used, but the contrast between the bacteria and pigments is not so definite and often the 2 are confused. Differentiation can further be made by fixing the material for examination to the slide and studying an unstained preparation. Here again, the normal color of the pigments is seen. The unstained *B. leprae*, in contrast, can only be observed when viewed in transmitted light, except for their chromatic "granules" which appear as small, round, blue-black bodies.

In conclusion, we wish to point out the close morphological resemblance of the rod-shaped pigments of the chick retina and their "globus" arrangement to the *B. leprae* and "globi" found in leprous tissue. Emphasis is placed upon the possibility of confusing these normal retinal structures with the *in vitro* multiplication of the leprosy bacillus in a minced chick embryo culture medium.