

from normal saliva is equivalent to 10.5 ± 4.6 mg. % of ethyl alcohol.

A procedure for the direct determination, without distillation, of ethyl alcohol in saliva is described. The results are 11.2 ± 3.3 mg. % higher than by the method of Friedemann and Klaas.

9696

Inhibitory Effects of Male Sex Hormone on Human Menstruation and Their Evaluation by Vaginal Smears.*

GEORGE N. PAPANICOLAOU, HERBERT S. RIPLEY AND EPHRAIM SHORR.

From the Departments of Anatomy, Psychiatry, and Medicine, Cornell University Medical College, and the New York Hospital.

The suppressive effect of the secretions of the male gonads on the female sexual functions of mammals has been known for a long time. Prior to the isolation of the active principle of the testis, evidence of this effect was obtained from studies of cases of hermaphroditism, gonadal transplants, studies on freemartins, and experiments with parabiotic twins.

With the isolation of the male sex hormone, experimental evidence has been obtained of the inhibitory effect of this hormone on the sex cycle of female rodents.¹ Recently a similar effect on menstruation in primates has been demonstrated.²

The absence of comparable studies in the human has prompted this report on the effect of the male sex hormone on the menstruation of a young woman. The results obtained with the treatment of this case are in agreement with the experimental findings in animals. Furthermore, they were complemented by observations of significant morphological changes occurring in the vaginal fluid which were revealed by studies of vaginal smears.

The subject was a young woman of 18 with a history of premenstrual depression, dysmenorrhea, moderate menorrhagia, and occasional premenstrual bleeding. Physical examination was es-

* This work has been aided by grants from the Committee for Research on Sex Problems, of the National Research Council, and from the Josiah Macy, Jr., Foundation.

¹ Robson, J. M., *PROC. SOC. EXP. BIOL. AND MED.*, 1936, **35**, 49.

² Zuckerman, S., *Lancet*, 1937, **233**, 676; Hartman, O. G., *PROC. SOC. EXP. BIOL. AND MED.*, 1937, **37**, 87.

sentially negative; the pelvic organs were normal. Menarche was at 13 years. The menstrual flow lasted 6-8 days and tended to be profuse. The intervals were fairly regular, usually about 30 days with an occasional variation of a few days. There was no history of amenorrhea.

Prior to treatment with male sex hormone, the patient was observed for 4 consecutive menstrual cycles, during 2 of which she received a series of injections of estradiol benzoate (Progynon-B).† This resulted in a shortening of the interval, and some diminution in dysmenorrhea. The length of these cycles and the time when vaginal smears were started are given in Chart 1.

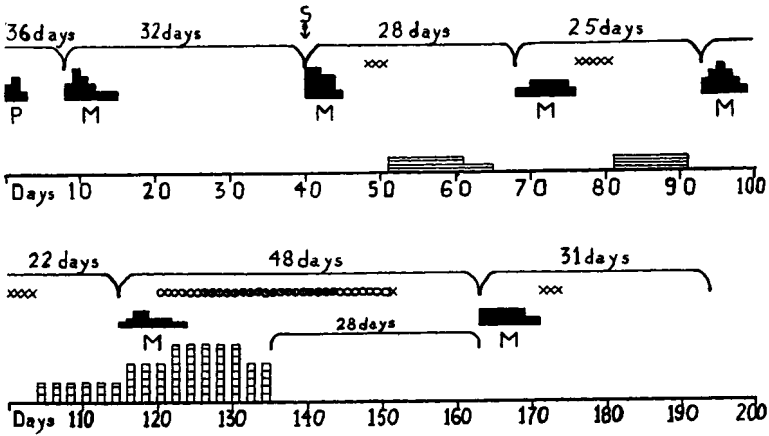


Chart I shows menstrual history and effect of treatment with estrogenic and with male hormone upon the menstrual cycle and the vaginal secretion of a young woman.
M = menstrual bleeding; one square scant, two moderate, three profuse, four excessive.
P = premenstrual bleeding. **S** = daily vaginal smears begun.
 = administration of estrogenic hormone (estradiol benzoate); each horizontal line = 500 Rat Units.
 = administration of male hormone (testosterone propionate); each square = 10 mg.
X = vaginal smear indicative of follicular activity, **O** = transitional smear types preceding and following the atrophic menopausal type, **⊙** = atrophic menopausal smear type.
● = menopausal smear type with abundant mucus.

CHART 1.

Beginning with the 40th day of observation, vaginal smears were taken daily. They showed somewhat subnormal follicular reactions occurring at the usual time, midmenstrually, and a fairly typical premenstrual phase with numerous bacteria resembling the *bacillus vaginalis*.

Shortly after the follicular phase, on the 12th day of the fourth

† We are indebted to Dr. E. Schwenk and Dr. G. Stragnell of the Schering Corporation for the generous supply of testosterone propionate (Oreton) and estradiol benzoate (Progynon B).

cycle, treatment was begun with intramuscular injections of testosterone propionate (Oreton).† During the remainder of this menstrual cycle 25 mg. of Oreton were given every other day. The next menstruation occurred on the 22nd day of the cycle and was definitely scantier. The dose was then increased to 50 mg., and later to 75 mg. every other day.

The first deviation from the normal vaginal smear was noted on the 6th or 7th day of menstruation (14-15 days from the beginning of treatment). There was a gradual replacement of the usual large squamous epithelial cell types characteristic of the normal cycle by smaller, rounder, and more compact cells with large, well-preserved nuclei.

On the 11th day (19th day of treatment) the smear consisted almost entirely of such round cells. On the 12th day of this cycle (20th day of treatment) leucocytes appeared in large numbers, and the smear became typical of the atrophic menopausal picture.³ This type of smear persisted, with slight variations throughout the course of treatment, and for 5 days after treatment was stopped. Occasional erythrocytes were present, as is common in such smears.³

On the 26th day (6 days after cessation of treatment) some increase was seen in the amount of mucus, which lasted 4 to 5 days, with an increased number of erythrocytes and fibrination. The prevailing cells were still of the "deep" menopausal type. On the 31st day of this cycle (11th day after discontinuation of treatment) leucocytes began to decrease. A few isolated cornified cells were noted on the 34th day of the cycle.

By the 37th day (17 days after treatment was stopped) a greater number of the large superficial squamous cells appeared including a few cornified cells, replacing the small "deep" cells. This indicated a resumption of ovarian follicular activity. On the 39th day, the smear was completely dominated by superficial squamous cells.

On the 40th day, the vaginal smear began to assume a premenstrual character with the reappearance of the bacillary flora originally present. It is of interest to note that this bacillary flora was absent during the induced menopausal phase. On the 48th day, exactly 28 days after the last injection of Oreton, menstruation was resumed. The flow lasted 8 days and was moderate in amount. It was followed by a weak follicular reaction, as before treatment, and then by the usual premenstrual picture, up to the next menses, which appeared on the 31st day. No masculinizing effects were observed in the patient during the period of treatment.

³ Papanicolaou, G., and Shorr, E., *Am. J. Obst. and Gyn.*, 1936, **31**, 806.

The above observations have been corroborated by similar studies in other patients in whom the smear changes have been correlated with biopsies and hormonal assays. These will be reported subsequently.

Conclusions. A study is presented in which the administration of testosterone propionate interrupted regular menstrual cycles in a young woman. Menstruation was resumed after cessation of treatment with this hormone. Vaginal smears showed that during the period of induced amenorrhea there was a replacement of the normal smear picture by one of the typical atrophic menopausal type, indicating a temporary suppression of ovarian follicular activity. This smear type was preceded and followed by characteristic intermediate stages and persisted throughout the course of treatment, and for a short time afterward. It was then followed by gradual resumption of follicular activity and a normal smear picture. The next menses occurred 28 days after the last dose of Oreton and about 12 to 13 days after the establishment of follicular activity.

This study furnishes a method for controlling the use of male sex hormone in women, and for inducing a temporary cessation of their menstrual cycle.

9697

Blood Oxygen Changes in Intermittent Claudication.

J. ROSS VEAL AND WILLIAM M. McCORD. (Introduced by
H. H. Beard.)

From the Departments of Surgery and Biochemistry, School of Medicine, Louisiana State University, and the Charity Hospital of Louisiana, New Orleans.

Although intermittent claudication can be readily produced experimentally by obstruction of the arterial and venous circulation in a normal extremity, the pathologic state thus precipitated is widely different from the pathologic state which is seen in gradually developing arteriosclerosis. Arteriosclerotic subjects who exhibit the symptom complex of intermittent claudication present varying degrees of arterial obstruction, but no venous obstruction of any degree.

In artificially produced intermittent claudication there is a marked lowering of the oxygen content of the venous blood. In order to determine exactly what changes occur in the stage of intermittent