

Since Russell has reported that the effect of anterior pituitary extracts in preserving muscle glycogen may be obtained in the absence of the adrenals, it is still possible that this gland secretes 2 substances affecting carbohydrate metabolism: (a) the adrenotropic principle and (b) a "glycostatic" principle which affects the tissues directly.

*Summary.* The injection of adequate amounts of either adrenal cortical extract or the crystalline compound B of Kendall will not only prevent the depletion of the carbohydrate stores of fasted hypophysectomized rats, but will also restore them after they have been depleted by fasting.

### 9918

#### Effect of Absolute and Partial Vitamin C Deficiency on Healing of Wounds.\*

MAX TAFFEL AND SAMUEL C. HARVEY.

*From the Department of Surgery, Yale University School of Medicine.*

It is now well established that the intercellular substances in general, and the collagen of all fibrous tissue structures in particular require ascorbic acid for their production and maintenance. Aschoff and Koch<sup>1</sup> made thorough postmortem studies of World War soldiers who had died of scurvy, and demonstrated constant pathological changes in the supporting tissues of the body. Höjer<sup>2</sup> found a general atrophy of the connective tissue in scorbutic guinea pigs, and pointed out for the first time a general deficiency in the formation of collagen. In a series of more recent communications Wolbach<sup>3, 4, 5</sup> and his collaborators confirmed the observations of Höjer, and conclusively showed that ascorbic acid is intimately concerned with the synthesis and maintenance of intercellular supporting materials. Jeney and Törö,<sup>6</sup> when they added ascorbic acid to the nutrient medium of a culture of fibroblasts *in vitro*, found a marked increase in the number of collagen fibrils that were produced.

---

\* The expense of this investigation was defrayed by Davis and Geck, Inc.

<sup>1</sup> Aschoff, L., and Koch, W., *Skorbut*, Jena, 1919.

<sup>2</sup> Höjer, J. A., *Acta Pædiat.*, 1924, **3**, 8 (supp.).

<sup>3</sup> Wolbach, S. B., and Howe, P. R., *Arch. Path. and Lab. Med.*, 1926, **1**, 1.

<sup>4</sup> Wolbach, S. B., *Am. J. Path.*, 1933, **9**, 689.

<sup>5</sup> Menkin, V., Wolbach, S. B., and Menkin, M. F., *Am. J. Path.*, 1934, **10**, 569.

<sup>6</sup> Jeney, A. V., and Törö, I., *Virchows Arch. f. path. Anat.*, 1936, **298**, 87.

Since the repair and tensile strength of soft tissue wounds are direct functions of fibroblastic proliferation and collagen formation, it is at once apparent that Vitamin C may play a prominent rôle in the phenomenon of wound healing. Saitta<sup>7</sup> reported a delayed healing of exposed surface wounds in guinea pigs that had been kept on a Vitamin C deficient diet for more than 15 days. On the other hand, when a Vitamin C containing extract was applied directly to the wound, the healing time was appreciably diminished, regardless of whether the animals were maintained on a normal or a scorbutic dietary regime. He determined the rate of healing by actual daily measurements of the length and breadth of the wound. Lauber<sup>8, 9</sup> excised square measured blocks of skin and subcutaneous tissue in experimental animals and noted the time required for complete healing and epithelialization of the wound. He found no acceleration in the healing of such wounds in guinea pigs which received subcutaneous injections of either small or large doses of ascorbic acid. The healing time of similar skin defects in 3-month-old mice was reduced by 3 days when strong concentrations of cevitamic acid were applied to the wound surface. Proto,<sup>10</sup> repeating Lauber's experiments in pigeons, found no significant change in the healing time of measured skin defects when Vitamin C was administered topically, orally or through both routes at once. Lanman and Ingalls<sup>11</sup> noted imperfect healing of operative incisions in guinea pigs maintained on a low intake of ascorbic acid. The tensile strength of wounds of the stomach and the abdominal wall of such animals, measured 10, 20, and 30 days postoperatively, was greatly inferior to that observed in normal control animals.

This series of experiments was carried out to determine the effect of absolute and partial Vitamin C deficiency on the healing of stomach wounds during the first 14 days after operation. Earlier reports from this laboratory have indicated that at the end of this period a wound in the stomach has attained almost its maximal tensile strength. The tensile strength of the wound was used as an index of healing. Young guinea pigs weighing about 250 g were divided into 3 groups: (1) normal control, (2) absolutely scorbutic, (3) partially scorbutic. All animals prior to the beginning of the experiment had been maintained almost from birth on a stock diet con-

---

<sup>7</sup> Saitta, S., *Scritti biol.*, 1929, **4**, 301.

<sup>8</sup> Lauber, H. J., *Beitr. Z. klin. Chir.*, 1933, **158**, 293.

<sup>9</sup> Lauber, H. J., *Beitr. Z. klin. Chir.*, 1935, **161**, 565.

<sup>10</sup> Proto, M., *Ann. ital. di chir.*, 1936, **15**, 31.

<sup>11</sup> Lanman, T. H., and Ingalls, T. H., *Ann. Surg.*, 1937, **105**, 616.

taining ample amounts of lettuce, kale, alfalfa, hay and celery trimmings. The scorbutigenic diet employed was a variant of the soy bean cracker meal first described by Cohen and Mendel<sup>12</sup> and subsequently modified by Wolbach.<sup>3</sup> It consisted of: soy bean meal 50, rolled oats 29, dried milk powder 10, Brewer's yeast 4, butter 5, calcium carbonate 1, sodium chloride 1. The soy bean meal was autoclaved at 15 lb for one hour. The dried milk powder was heated in a shallow pan for 3 hours at 100°C and frequently turned so as to expose all of it to the air. In addition one cc of cod liver oil was administered twice weekly by pipette. Distilled water was given *ad lib*. The diet contained adequate amounts of the necessary proximate principles, minerals, and vitamins, except for Vitamin C in which it was entirely lacking. On this diet with or without the addition of ascorbic acid the great majority of the animals either maintained their weight or increased it. Those that lost weight revealed no significant change in the bursting strength of their stomach wounds.

I. Control Group—31 animals. This group was maintained throughout the entire duration of the experiment on the scorbutic diet which was supplemented by daily administration by pipette of a solution containing 5 mg of ascorbic acid. (Harris and Ray<sup>13</sup> and later Dann and Cowgill<sup>14</sup> have shown that guinea pigs weighing about 250 g require about 2 mg of cevitamic acid daily as the minimum dose for full tooth protection.) The animals were kept on this regime for one week in order to equalize as much as possible the concentration of Vitamin C in the body depots. On the 8th day a longitudinal wound measuring about 2 cm in length was made under ether anesthesia through the anterior wall of the stomach at its cardiac end. The wound edges were immediately reapproximated in one layer with a running continuous Connell suture of No. 000 plain catgut which, as has been previously shown, loses its tensile strength well within the fourth day.<sup>15</sup> The abdominal wall was closed with 2 layers of fine No. A silk. Strict aseptic precautions were observed. On each of the 4th, 6th, 8th, 10th, 12th, and 14th postoperative days 4 to 6 animals were sacrificed, and the strength of the wound immediately determined by distending the stomach with air and noting its bursting point. The details of this method were described by Harvey and Howes.<sup>16</sup> Inasmuch as it has been

<sup>12</sup> Cohen, B., and Mendel, L. B., *J. Biol. Chem.*, 1918, **35**, 425.

<sup>13</sup> Harris, L. J., and Ray, S. N., *Biochem. J.*, 1933, **27**, 2016.

<sup>14</sup> Dann, M., and Cowgill, G. R., *J. Nutrition*, 1935, **9**, 507.

<sup>15</sup> Howes, E. L., *J. A. M. A.*, 1928, **90**, 530.

<sup>16</sup> Harvey, S. C., and Howes, E. L., *Ann. Surg.*, 1930, **91**, 641.

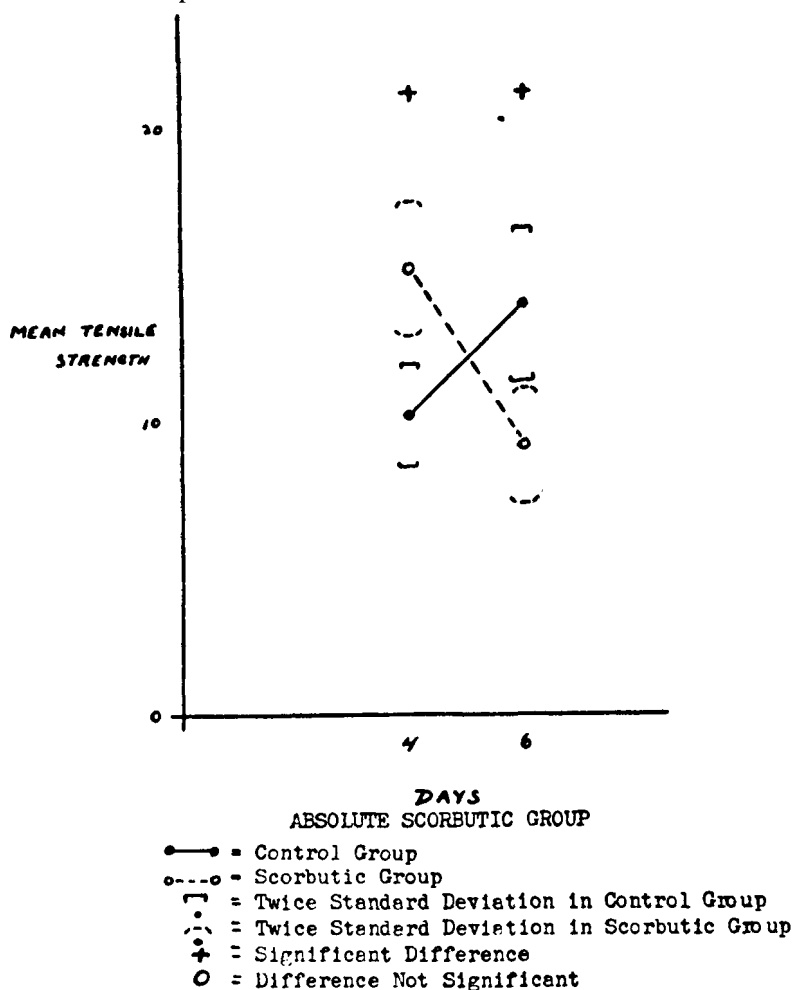
shown that for approximately 4 days after the injury, the wounds had only the strength contributed by the holding power of the sutures, no studies were made during this first phase of healing.

II. Absolutely Scorbutic Group—20 animals. This group was similarly maintained for one week on the experimental diet supplemented daily with 5 mg of ascorbic acid. On the 8th day the ascorbic acid was abruptly withdrawn. After 21 days on the scorbutigenic diet without Vitamin C the animals were operated upon, and wounds in the stomach exactly similar to those of the control group were made. At this time all animals had obvious signs of grave scurvy. The costochondral junctions and the epiphyses of the long bones, especially at the wrist and ankle, were thickened, bulbous and tender. Although only rare spontaneous fractures were noted, the long bones were so fragile that frequently even gentle handling was sufficient to crack them. Scattered small and large hemorrhages were observed in the subcutaneous tissues of the limbs and particularly on the abdominal wall where the animals rubbed themselves against the floor of the cage. At first irritable and easily excitable, the guinea pigs later became listless and apparently avoided moving about in the cage. Nearly all developed diarrhea with blood streaking of the stool. Many had a marked prolapse of the rectum. In some instances the incisor teeth became loose, but in none were hemorrhagic gums seen. The weight curve presented no constant change. Some animals lost weight, while others did not. This group at first contained 36 animals. However, after developing manifest scurvy, they died so rapidly that only 20 could be retrieved for study. Determinations of the breaking strength of the wounds could be made only on the 4th and 6th postoperative days since no member of this group survived more than 7 days after the operation.

III. Partially Scorbutic Group—34 animals. This group was also started on a one-week regime of the experimental diet plus daily doses of 5 mg of ascorbic acid. On the 8th day the ascorbic acid was withdrawn and the animals kept on the deficient diet for 14 days in order to deplete the Vitamin C in their body depots. At the end of this period they were put on a maintenance dose of 0.2 mg of ascorbic acid every other day until the termination of the experiment. After 10 days on this low Vitamin C intake, wounds were made in their stomachs. Most of the animals gained weight and survived long enough to permit determinations of the bursting strength to be carried out from the 4th through the 14th postoperative day. Postmortem examinations were made on all the animals and in each instance there were unmistakable gross evidences of

scurvy. The wrist and ankle joints were beaded and the peri-articular ligaments thickened and infiltrated with old and fresh extravasations of blood. The long bones were thin and brittle. The marrow was gelatinous. There were scattered hemorrhages in the subcutaneous tissues and especially in the muscles of the thighs. In view of the obvious gross manifestations of scurvy, it was not felt necessary to get any confirmatory evidence from histological examination of the teeth and gums.

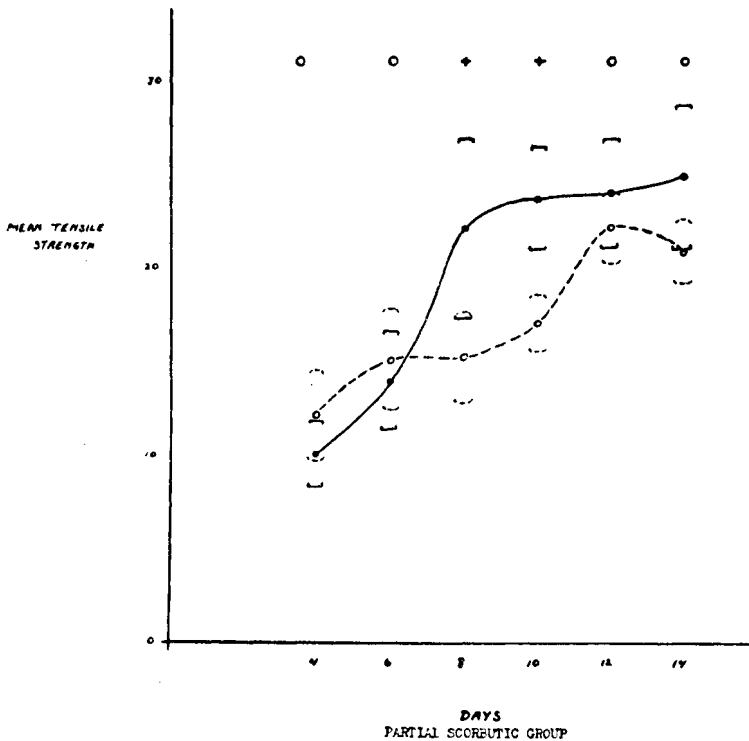
The stomach wounds of the animals in all 3 groups healed *per primam* except in 3 instances where a small walled off abscess was present at the operative site. One of these occurred in the control



GRAPH 1.

group, the other 2 in the partially scorbutic group. These 3 animals were discarded. Adhesions between the stomach and the liver or omentum were rare. In no instance were they so stubborn that they could not be easily divided to expose the healing wound. In each group the averages of the breaking strength for every postoperative interval, as well as the standard deviation were computed and plotted (Graphs 1 and 2). Fisher's<sup>17</sup> formula for small samples was applied to determine whether the difference in the means of 2 groups was statistically significant.

*Results.* In guinea pigs kept on a normal well-balanced diet, the curve of healing of stomach wounds as measured by their tensile strengths was parallel to that noted in soft tissue wounds of other experimental animals. After the fourth postoperative day there was an abrupt rise in the curve which continued until about the tenth day, when the velocity progressively decreased and slowly approached the asymptote. During this latter phase of healing some of the wounds became stronger than the surrounding uninjured



GRAPH 2.

Legend same as in Graph 1.

<sup>17</sup> Fisher, R. A., *Statistical Methods for Research Workers*, Edinburgh, 1934.

TABLE I.

Day	Normal Control Group			Absolutely Scorbutic Group			Mathematically Significant Difference of Means		
	No. of animals	M.T.S.*	2 S.D.†	Bursting Site	No. of animals	M.T.S.*		2 S.D.†	Bursting Site
4	6	10.16	1.74	All at incision	11	15.3	2.26	All at incision	Yes
6	5	14.0	2.68	" " "	9	9.25	2.04	" " "	"

\*M.T.S. = Mean of Tensile Strengths.

†2 S.D. = Twice the Standard Deviation from the Mean.

TABLE II.

Day	Normal Control Group			Partially Scorbutic Group			Mathematically Significant Difference of Means		
	No. of animals	M.T.S.*	2 S.D.†	Bursting Site	No. of animals	M.T.S.*		2 S.D.†	Bursting Site
4	6	10.16	1.74	All at incision	5	12.2	2.4	All at incision	No
6	5	14.0	2.68	" " "	6	15.2	2.7	" " "	"
8	4	22.25	4.78	" " "	6	15.5	2.46	" " "	Yes
10	4	23.75	2.74	2 elsewhere	6	17.3	1.5	" " "	"
12	6	24.16	2.90	5 "	6	22.3	1.96	3 elsewhere	No
14	6	25.0	3.82	4 "	5	20.6	1.86	1 "	"

\*M.T.S. = Mean of Tensile Strengths.

†2 S.D. = Twice the Standard Deviation from the Mean.

stomach wall, the bursting site occurring at places elsewhere than in the wound. Partial starvation, as manifested by a loss of body weight, seemed to have no effect on the progress of the healing.

In absolute scurvy, the "scurbut gravior manifestus" of Höjer, there was observed on the fourth postoperative day a mathematically significant increase in the strength of the wound over that of the control animals for the same interval. This finding was checked and found to be true in 2 separate groups of scorbutic animals. The results were pooled and expressed in Table I and Graph 1. The significance of this increase is not evident. Inasmuch as at this stage the strength of the wound is dependent almost entirely upon the extent of the fibroplasia, it is suggested that the absolute deficiency may in some way act as a stimulus for the increased proliferation of fibroblasts in the very early stages of healing. This, however, has not been proved. At the 6-day interval the strength of the wound in the scorbutic guinea pig was markedly inferior to that of the normal animal. This can be fairly attributed to the inadequate collagen formation known to occur in Vitamin C deficiency.

The healing curve in the partially scorbutic guinea pig is shown in Graph 2. On the fourth and sixth days there were no appreciable deviations from the normal. At the 8- and 10-day intervals, however, there was a significant diminution in the tensile strength, which during the 12th and 14th days again approached the normal value. This relative weakness in the wounds of the experimental group was further emphasized by a comparison of the sites of the bursting point. Out of a total of 16 control animals in the 10-, 12-, and 14-day intervals, the distended stomachs ruptured at places elsewhere than the operative incision in 11 instances. On the other hand, of 17 scorbutic animals for the same time period, in only 4 was the bursting point not at the site of the wound (Table II). The delayed healing of the wound in the partially scorbutic animal may again be directly related to the deficient or imperfect deposition and maintenance of collagen. The inferior strength of the wound at 8 and 10 days is interesting when it is remembered that clinically the great majority of wound disruptions occur during this same postoperative interval. These experiments confirm the suggestion of Lanman and Ingalls that Vitamin C deficiency in man, even when it is partial, may indeed be one of the major causative factors in those cases of wound disruption where there is no evidence of infection of the wound and where the patients for one reason or another have been on an inadequate dietary regime.