

streptococci. We have found it to be simple, rapid, economical and satisfactory.

In the absence of standard type-cultures, the production of type-agglutinating sera was necessarily slow. Immunization of rabbits was first carried out with several strains of diphtheric bacilli chosen at random. Other strains found not to be agglutinated by these sera were used to produce new sera. In this way, 10 different types have been obtained.

Typing was done by placing drops of a thick bacterial suspension on a slide; then with each drop, a loopful of one of the agglutinating sera was mixed. With the aid of a hand-lens, agglutination in one of the drops could be observed immediately.

By this method, 95 strains of virulent diphtheric bacilli isolated from clinical cases of diphtheria treated in this hospital during the last 2 years have been classified as follows:

(1) Type D30	23 strains	(5) Type D14	10 strains
(2) " D25	18 "	(6) " D40	8 "
(3) " D41	16 "	(7) " 6287	5 "
(4) " 12190	12 "	(8-10) " D15, D43, 1382,	1 strain
			each

Type D40 and 6287 strains showed slight cross-agglutination. However, the type-specificity of all the sera has been confirmed by the reciprocal absorption-tests.

Summary. For serological classification of *C. diphtheriæ* the slide-agglutination technic has been used. Of 95 strains obtained locally from clinical cases, 92 fell into 7 distinct serological types.

10673

Experimental Trichophytid in Guinea Pigs.*

ARTHUR T. HENRICI.

From the Department of Bacteriology and Immunology, University of Minnesota, Minneapolis, Minn.

The term "trichophytid" was introduced by Bloch to designate a generalized eruption occurring during the course of a localized trichophytosis. It has also been used to designate localized skin lesions

* Aided by a grant from the Graduate School of the University of Minnesota. Assistance in the preparation of this material was furnished by the personnel of Works Progress Administration, Official Project No. 665-71-3-69, Subproject No. 274.

at a distance, and different, from a primary trichophytosis. These reactions have been thought to be due to a blood-borne distribution of either the parasite or its products to the skin, which has become sensitized as a result of the primary infection. This theory is based almost entirely upon clinical observations. Although a number of workers have reported on experimental trichophytosis, and on the occurrence of allergic sensitization in the experimental disease,¹ I have been unable to find any reports of experimental production of a generalized eruption in animals, comparable to human trichophytid.

The experiments here reported have been carried on with a single strain of *Trichophyton mentagrophytes* (= *Tr. gypseum*) typical in all respects, isolated from a human infection of the nape which was probably contracted from a horse. Guinea pigs were inoculated by scarifying some of the fungus into the skin of the abdomen (previously depilated by barium sulphide) with sandpaper. Signs of infection were noted on the fourth or fifth day; the lesions extended a centimeter or two beyond the scarified area, and reached their maximum development about the tenth day; they were usually completely healed after 4 to 5 weeks.

To provoke an allergic reaction in the infected guinea pigs, they have been reinoculated with live spores, or with cell sap expressed from the mycelium, or with crude polysaccharide extracted from the mycelium. Spore suspensions were obtained by washing the surface of large (25 mm) Sabouraud agar slant cultures with physiological salt solution. Cell sap was obtained by collecting the mycelium from 7-day-old cultures in Sabouraud's liquid medium, squeezing it as dry as possible, mincing it finely by repeated passage through a food chopper, and expressing the sap by means of a hydraulic press. The liquid so obtained was passed through a Seitz filter. The remaining mycelium, now nearly dry, and weighing about 150 g, was suspended in a liter of 1% NaOH solution and heated just to boiling. Hydrochloric acid was added to the alkaline extract (separated from the mycelium) until a voluminous precipitate formed. After filtering, the liquid was added to 10 volumes of alcohol. The resulting precipitate was collected, dissolved in 100 cc of water. Crystals of trichloroacetic acid were added until no further cloudiness appeared. After removing this precipitate by filtering, the remaining liquid was neutralized and added to 10 volumes of alcohol. The resulting precipitate was collected and dried. This precipitate is called crude polysaccharide.

¹ This literature has recently been reviewed by De Lamater, E. D., and Benham, R. W., *J. Invest. Dermatol.*, 1938, **1**, 451, 469.

Twenty-two infected guinea pigs have been reinoculated intraperitoneally with live spores, in doses of either one-half or one agar slant, at intervals from 10 to 52 days after the primary scarification. All of these have exhibited some degree of reaction, but sensitivity is greatest at the time when the primary lesion has nearly, but not entirely healed, *i. e.*, about 25 to 30 days. Such animals show, 24 hours after the administration of the "shock dose," a marked erythema observed on all exposed areas of the skin (the depilated area of the primary lesion, the paws, ears, scrotum, nose and lips). In 4 cases the animals were completely depilated posterior to the shoulders. These showed a general erythema, most marked on the ventral surface, but visible on the back when compared with control infected animals, similarly depilated, which had not been reinoculated. In another 24 hours, desquamation begins. This is at first most marked at the site of the primary lesion, but extends beyond it; in depilated animals it is observed over the entire ventral surface (Fig. 1). Desquamation of the back has not been observed. Desquamation is complete in 3 to 5 days. In from 2 to 5 days there occurs desquamation of the paws, the skin peeling off in large plaques (Fig. 2). This may be completed in 24 hours, so that if the animals are not carefully watched it could be overlooked. Simultaneous with the peeling of the paws, the ears become covered with fine scales, which may persist for a week. One animal showed marked scaling of the face, beginning about the nose; it may have had an accidental primary lesion about the nose.

Animals inoculated earlier or later than the period of maximum sensitivity have all reacted to a lesser degree. In some the skin reac-

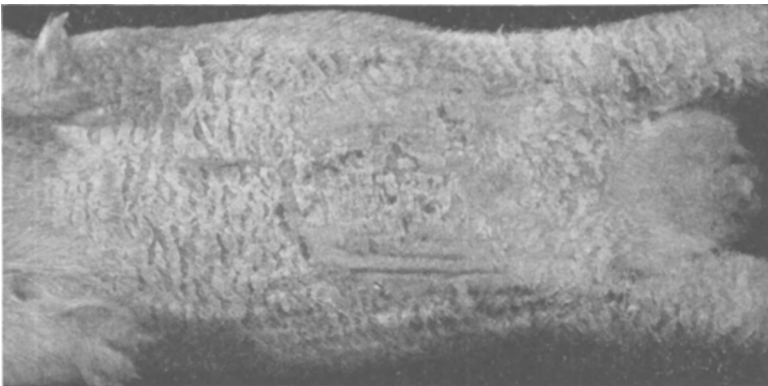


FIG. 1.

Generalized desquamation following intraperitoneal injection of "shock dose" of *Tr. mentagrophytes* into sensitized guinea pig.

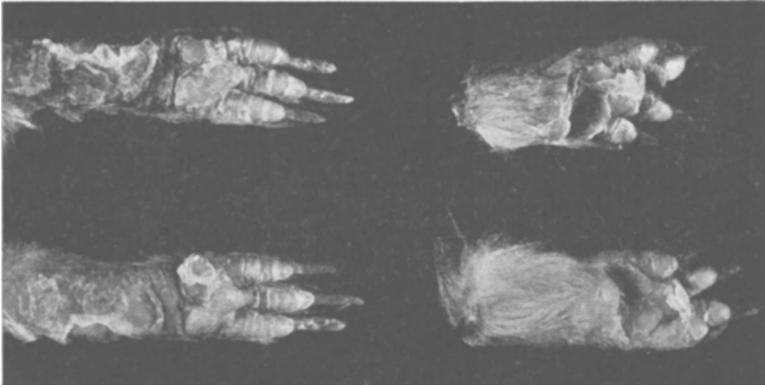


FIG. 2.

Desquamation of paws following intraperitoneal injection of *Tr. mentagrophytes* into sensitized guinea pig.

tion was limited to the area of the primary infection and the paws or ears. Fourteen noninfected animals inoculated intraperitoneally with live spores have failed to show skin reactions of any sort. Four of these were completely depilated posterior to the shoulders before inoculation.

Four sensitized guinea pigs were given 5 cc of sterile cell sap intraperitoneally. They reacted in a manner identical with those which had been reinoculated with live spores. In 2 depilated animals complete desquamation of the ventral surface was noted. Peeling of the paws and scaling of the ears occurred in all. One animal given 0.2 cc of cell sap intracutaneously on the back showed a local area of redness at the site of injection, and desquamation of the primary lesion (which had healed), but no general reaction.

Two guinea pigs were given 50 mg of polysaccharide intraperitoneally. They showed general erythema followed by desquamation precisely as in those reinoculated with the live spores. Three additional animals received 10 mg of polysaccharide subcutaneously, and showed similar general reactions. Another, given 2 mg intracutaneously on the back, showed an intense local reaction with central necrosis, and general erythema, followed by desquamation of the paws, ears, and abdomen.

Two depilated noninfected controls were inoculated intraperitoneally with 5 cc of cell sap, and 2 others with 50 mg of polysaccharide, without any observable reaction. Six animals which had received a primary injection of live spores intraperitoneally were reinoculated in the same manner after 3 to 4 weeks. They showed no skin reactions.

Two sensitized guinea pigs which had reacted strongly to an intraperitoneal inoculation of live spores, were reinoculated with live spores after 3 weeks, and again reacted in a manner similar to the first reaction. Four animals which had reacted to intra- or subcutaneous injections of polysaccharide reacted again to live spores after a 3-week interval. One animal which had reacted to an intraperitoneal injection of cell sap, reacted again to an injection of live spores a month later; 2 months later, *i. e.*, 4 months after the initial scarification, it reacted to another injection of live spores by desquamation of the area of the original infection, but showed no generalized reaction.

I have looked for fungi in scales from the paws and ears and from the abdomen distant from the primary lesion without success in 6 cases. Cultures of scales from these animals also failed to show the presence of *Tr. mentagrophytes*. Sections of skin from paws and ears stained by the Gram-Weigert method have failed to reveal any fungi in 10 cases. Blood cultures have been made from 4 sensitized animals at intervals from 4 to 48 hours after intraperitoneal inoculation of live spores. They remained sterile.

In nearly all animals which developed trichophytid, enlargement of the scrotum was a marked feature. This was due in part to congestion and edema of the skin, but with those animals which were given live spores intraperitoneally, in the majority of cases palpable nodules developed in the testes after 4 to 7 days. These were found on autopsy to be confined to the surface of the testis, and to be part of a general peritoneal reaction, nodules occurring also in the omentum and on the parietal peritoneum. Similar but obviously lesser lesions were found in non-sensitized animals which had been inoculated intraperitoneally. These abdominal lesions are being studied further.

Summary. Guinea pigs which had recovered from infection with *Trichophyton mentagrophytes* reacted to intraperitoneal injections of live spores, cell sap, or polysaccharide by generalized erythema of the skin followed by desquamation. This condition is considered identical with trichophytid in human cases. No organisms could be found in the allergic lesions. These experiments strongly support the theory that trichophytid is an allergic response of the skin to substances in solution distributed to it by the blood.